

Hashitoxicosis: A Case Report

Dhini Sylvana¹, Dharma Lindarto², Santi Syafril², Melati Silvanni Nasution², Dian Anindita Lubis², Stephen Udjung³

- 1 Student of Diabetes Metabolic Endocrine Subspecialist Education Program, Department of Internal Medicine, Faculty of Medicine, University of North Sumatera/RSUP Haji Adam Malik
- 2 Division of Diabetes Metabolic Endocrine Department of Internal Medicine, Faculty of Medicine, University of North Sumatera/RSUP Haji Adam Malik
- 3 Department of Anatomical Pathology/RSUP Haji Adam Malik

*Corresponding author:

Dhini Sylvana, MD.

Diabetes Metabolic Endocrine Subspecialist Education Program, Department of Internal Medicine, Faculty of Medicine, University of North Sumatera/RSUP Haji Adam Malik, Medan, Indonesia

Email: dhiniendokrin@gmail.com

ABSTRACT

Hashimoto Thyroiditis with Grave's disease/Hashitoxicosis is found in some cases, and this case report describes a case of a woman with Hashitoxicosis. A 27 year old woman came to polyclinic on 18th March 2024 with complain of a lump felt, fatigue, constipation and weight loss two month before she had weight gain later without any treatment. She was compositis, BP 149/90 mmHg, HR 87x/i, Wayne index 0, Billewicz score -22. TSH 93.40 mIU/mL and FT4 0.39 ng/dL, anti-TPO >1000 IU/mL, TRAb 2.46 IU/L. Thyroid ultrasound showed toxic diffuse struma, thyroid scintigraphy revealed enlarge lobes with high and even distribution and capture of radioactivity with conclusion Toxic Diffuse Struma, and cytologic examination showed colloid goiter. Patient was diagnosed as Hashitoxicosis and has been treated with levothyroxine 100 mg once daily. This woman was diagnosed as Hashitoxicosis based on clinical features of hypothyroidism at admission to polyclinic following clinical features of hyperthyroidism initially without any treatment, with laboratory results showed hypothyroidism with the increased of antibody for Hashimoto Thyroiditis and Grave's disease. Treatment with levothyroxine 100 mg once daily showed the decrease of TSH and normal FT4 level. We report a case of Hashitoxicosis based on clinical features of hypothyroid following hyperthyroidism initially, laboratory, thyroid ultrasound thyroid scintigraphy, and cytologic examination result. Treatment with levothyroxine showed improvement.

Keywords: Hashimoto's thyroiditis, graves' disease, hashitoxicosis

INTRODUCTION

Hashimoto's thyroiditis (HT), also known as an autoimmune disease of the thyroid gland, is often characterized by an enlarged thyroid gland, hypothyroidism, which damage to the thyroid gland occurs due to lymphocytic infiltration and elevated serum autoimmune antibody levels^{1,2}. Based on a worldwide meta-analysis study of 48 studies in 20 Europe, 16 Asia, 5 South America, 3 North America, and 3 Africa, the prevalence of HT was 7.5%. The prevalence of HT varies according to geography, namely Africa 14.2%, Oceania 11%, South America and Europe 8.0%, North America 7.8%, and Asia 5.8%.³ HT was diagnosed with anti-thyroid antibodies against peroxidase (TPOAb) and anti-thyroid antibodies against thyroglobulin (TGAAb), and it was confirmed using thyroid ultrasonography. In a study, 24 patients had hypothyroidism, and they were followed up during the period 2000–2016.

Following HT diagnosis, patients developed GD after a mean time of 38 ± 45 months, and levels of fT3, fT4, and TRAb were significantly higher, and TSH levels were significantly lower at the hyperthyroid state.⁴ 61-year-old woman who was diagnosed with hypothyroidism 30 years ago and then, the patient returned to the hospital in 2015 with a hypothyroid blood result with anti-TPO 83 IU/mL, elevated TRAb, and a hyperthyroid picture. In 2017, it was found that her TSH was completely suppressed, FT4 elevated, and then called this condition hypothyroidism conversion to hyperthyroidism.⁵ This case report describes a case of a woman, 27th years old with HT.

CASE ILLUSTRATION

A woman, 27 years old, came to the internal medicine specialist with complaints of a lump felt for two months. Complaints of pain and fever are not found. Complaints of palpitations were not found, complaints of a 2 kg weight loss were found, but then the weight rose again. Fast fatigue is found, thumping is not found, and

sweating is not found. A family history of the same disease was found that the patient's mother experienced the same thing but was only suctioned, and there was no routine medication. The patient stated constipation and urination were normal. The examination revealed CM sensorium, BP 149/90 mmHg, HR 87x/i, Wayne's Index 0, Billewicz score -22, thyroid ultrasound result 18/3/24 was struma diffuse toxic. The patient was advised to check TSH and FT4 at the next visit. On March 25, 2024, the results of TSH 93.40 mIU/mL and FT4 0.39 ng/dL were obtained, then referred to radionuclear for thyroid print examination. On April 5, 2024, a thyroid scintigraphy examination revealed enlarged lobes with high and even distribution and capture of radioactivity, which was concluded to be Struma Diffusa Toxic.

On cytologic examination of aspirate samples, cystic colloid goiter was found. Based on the results of history and examination, the patient was diagnosed with HT with Grave's Disease, also diagnosed as Hashitoxicosis. On the next visit on April 16, 2024, the patient was given Levothyroxine 1x100mg therapy for a month, then on April 18, an anti-TPO and TSH Receptor Antibodies (TRAB) examination was carried out with the results of anti-TPO >1000 IU/mL and On TRAB On 2.46 IU/L. On April 23, TSH and FT4 were re-checked with TSH 0.65 uIU/mL and FT4 86.20 ng/dL. On May 17, TSH 5.97 uIU/mL and FT4 1.34 ng/dL. On June 20, TSH 7.41 uIU/mL and FT4 1.06 ng/dL.

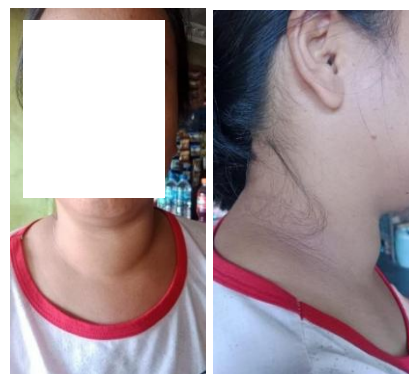

Figure 1. Goiter

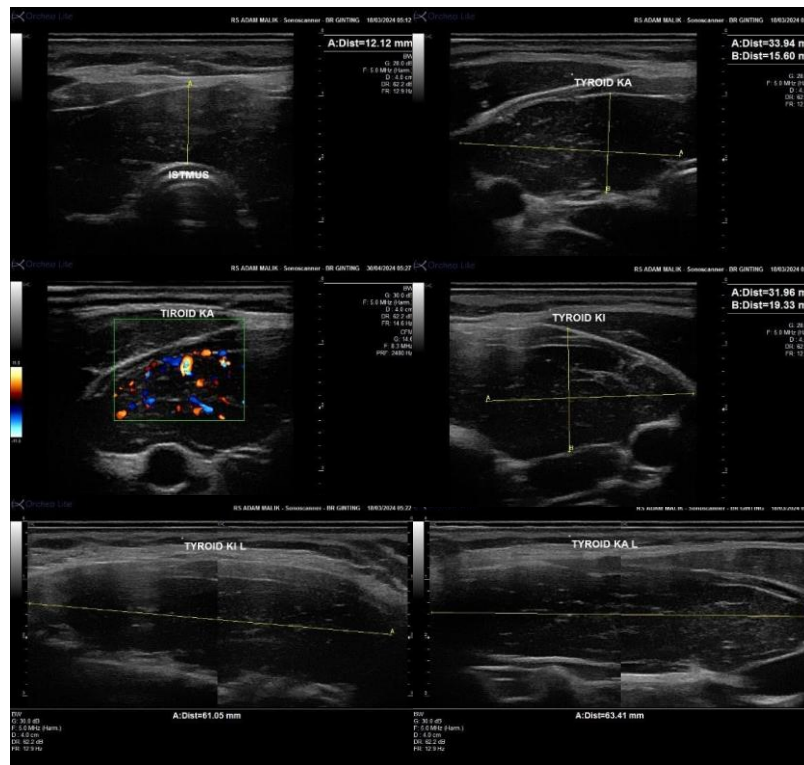


Figure 2. Thyroid ultrasonography

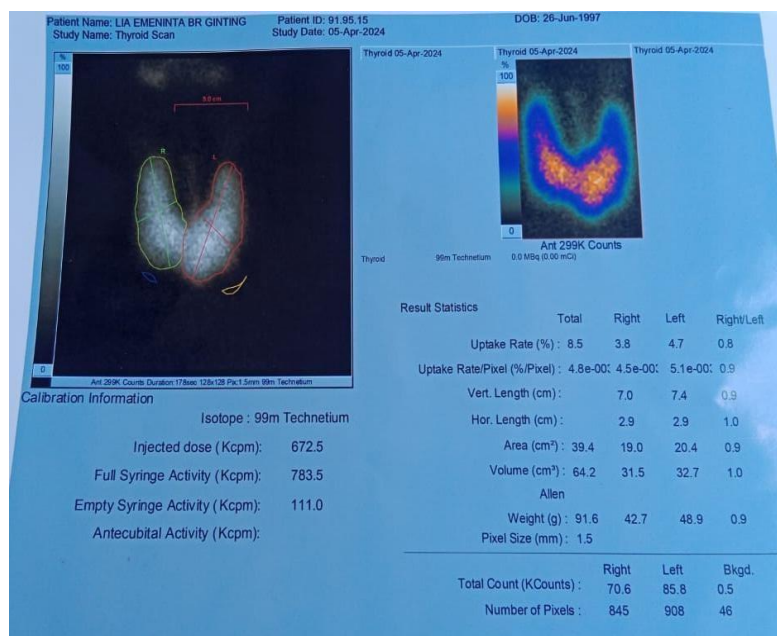


Figure 3. Thyroid Scintigraphy

DISCUSSION

In this case, the patient complained of a lump in the neck, no heart palpitations, and no profuse sweating. This condition caused by signs and symptoms in HT is linked to hypothyroidism they are goiter and decreased T4, cool and dry skin due to atrophy of the sweat glands, yellowish and thickened skin due

to accumulation of hyaluronic acid, coarse hair, loss of body hair, hoarse voice due to myxedema of the vocal cord, coarse facial features, facial edema, generalized edema, bradycardia and decreased amplitude of cardiac waves on electrocardiography, decreased cardiac output, delayed relaxation phase of the deep tendon reflexes, decreased

peristalsis leading to constipation or even ileus, hypotonia of the gallbladder and may lead to biliary stone formation. Patients with overt hypothyroidism could present as menorrhagia in women and include altered anovulatory cycles due to impaired conversion of estrogen precursors.⁶ Wayne's Index is a scoring tool for hyperthyroidism signs and symptoms. Nine symptoms and ten signs are listed and have positive or negative scores. The score ranges from 45 to -25. A score >19 is toxic hyperthyroidism, while a score <11 is euthyroidism, and a score 11-19 is equivocal. Though arrived at by trial and error, it has shown a diagnostic accuracy of 85%. Wayne's Index was earlier used to help diagnose hyperthyroidism and Grave's disease.⁷ In this case, the patient's Wayne's Index is 0, which means it can be assessed as not Grave's disease.

The Billewicz score consists of 13 assessments with a total score of +67 to -47. A score $\geq +25$ suggests hypothyroidism, -30 to +25 is subclinical hypothyroidism, and a score - of 30 or less excludes the disease. Diminished sweating is assessed in a warm room. Dry skin is defined as dryness of skin noted spontaneously. Cold intolerance is a preference for a warm room or extra clothing. Weight increase and constipation are scored as present. Hoarseness is assessed in speaking and singing, and paresthesia is scored based on subjective sensations. Deafness is defined as a progressive improvement of hearing. Slow movements are noted while observing the patient at present. Coarse skin and thickening are assessed over the hands, forearms, and elbows. Cold skin is assessed by comparing the patient's and examiner's skin. Periorbital puffiness is defined if it obscures the curve of the malar bone. Counting the pulse for the 30s and report bradycardia of the pulse <75/min. They elicit the ankle jerk when the patient kneels on a chair, grasping its back.⁸ In this case, the total Billewicz score is 22, which means that based on screening, the patient is concluded to have subclinical hypothyroidism.

In some patients with particularly pronounced thyroid destruction in the initial phase, Hashitoxicosis or HT in the hyperthyroidism stage maybe present due to the release of preformed thyroid hormones from destroyed follicles to the circulation. Primary hypothyroidism is generally considered "overt" when the TSH level is elevated and FT4 is low. Subclinical hypothyroidism is defined biochemically as an elevated TSH accompanied by normal FT4 and FT3. Condition of hypothyroidism is due to thyroid follicular cell destruction by infiltrating immune cells, leading to exposure of thyroid antigens (TPO and thyroglobulin [Tg]), further enhancing antibody production (TgAbs, TPOAbs) and aggravating destruction of thyroid follicles. Anti-TG antibodies attack a protein in the thyroid called thyroglobulin. Anti-thyroperoxidase (TPO) antibodies attack an enzyme called thyroperoxidase in thyroid cells that helps convert T4 to T3. Having TPO autoantibodies in the blood means the body's immune system attacked the thyroid tissue in the past. Most people with HT disease have these antibodies, although people whose hypothyroidism is caused by other conditions do not.^{6,9}

The thyroid ultrasound examination results found that the right and left lobes were dilated with heterogeneous parenchyma, no classification, and increased vascularity. There were no nodules, thickened isthmus, and no enlarged lymph nodes. The conclusion of the Thyroid ultrasound examination is Struma Diffusa Toxic. Anti-TPO >1000 IU/mL. Cytologic examination of aspirate samples revealed cystic colloid goiter. Based on the examination, the patient was diagnosed with HT because the diagnosis of HT is based on clinical symptoms of hypothyroidism, the ultrasound features of HT include decreased echogenicity, heterogeneity, hypervascularity, and presence of small cysts, and serum anti-TPOAbs are present. Candanwale et al. found 5 cases of HT with the colloid goiter on FNA examination out of 100 cases they studied. In their case, FNA smears showed moderate to severe background colloid

and lymphocytes infiltrating follicular cell clusters and Hurthle cells.^{10,11,6}

In this case, we found TSH 93.40 uIU/mL and FT4 0.39 ng/dL, anti-TPO >1000 IU/mL, and TRAb positive. TRAb suggests clinicians utilize a positive TRAb measurement over their clinical judgment to confirm a Graves' Disease (GD) diagnosis. A meta-analysis of 21 studies showed that the serum TSH-R-Ab concentration's overall pooled sensitivity and specificity measured with second- and third-generation binding assays were 97 and 98%, respectively.^{12,13} Thyroid scintigraphy examination, in this case, revealed enlarged lobes with high and even distribution and capture of radioactivity. Diffuse thyroid overactivity with a homogeneous distribution of the tracer, reduced uptake in major salivary glands, and low background, consistent with GD.¹⁴

In 2010, four case reports illustrated a subtype of Graves' disease where individuals with HT present with Graves' eye disease and elevated blood levels of stimulating antibodies. While the exact reason this occurs is unknown, researchers believe TSH receptors and antibodies are the links. As the concentration of thyroid stimulating and blocking antibodies changes, so does the clinical presentation of thyroid dysfunction. The thyroid cell might be 'attacked' by blocking and stimulating antibodies. Depending on the relative concentrations, hypothyroidism or hyperthyroidism may occur. So, the difference between HD and GD may be gradual and small.¹⁵

In some cases, as the autoimmune process progresses and the thyroid gland becomes damaged, a person with Graves' disease can develop HT. While symptoms can shift back and forth, it is more common for one clinical presentation to overshadow the other. For instance, in the most common presentation of this situation, there are more thyroid-blocking antibodies than stimulating antibodies, typically causing symptoms of hypothyroidism. It is also possible for a person to have both conditions concurrently. In this case, the immune system

produces stimulating and blocking antibodies, leading to fluctuating thyroid hormone levels and variable symptoms that shift between hypothyroid and hyperthyroid. When both conditions are present, one condition is still more likely to dominate in symptoms.¹⁶

HT usually presents as subclinical or overt hypothyroidism. In some cases, a patient has the signs and symptoms of hyperthyroidism in the initial presentation, and this condition is called Hashitoxicosis. Case report found anti-TPO >1000IU/mL, TSH suppressed, and FT4 elevated.¹⁷ One possible explanation of the unusual hyperthyroidism condition in HT patients was the presence of these stimulating antibodies apart from the destruction of thyroid follicles.¹⁷ In some cases, we found other patients had high TSH, low or normal FT4, and high anti-TPO, so the patients were diagnosed with HT and then got levothyroxine therapy for hypothyroidism. After a few months of therapy, the patient returned for follow-up and found TSH suppressed, FT4 elevated, and TRAb positive. The authors conclude that this condition is called GD following hypothyroidism or conversion of autoimmune hypothyroidism (HT) to GD.^{18,19} In a study, 24 patients had hypothyroidism and HT, followed by a phase of hyperthyroidism. They were followed up during the period 2000–2016. Following HT diagnosis, patients developed GD after a mean time of 38 ± 45 months. Levels of fT3, fT4, and TRAb were significantly higher, and TSH levels were significantly lower in the hyperthyroid state.⁴

In another case report, we found a similar case with our patient, a 61-year-old woman who was diagnosed with hypothyroidism 30 years ago. Then, the patient returned to the hospital in 2015 with a hypothyroid blood result with anti-TPO 83 IU/mL, elevated TRAb, and a hyperthyroid picture. In 2017, it was found that her TSH was completely suppressed and FT4 elevated. The authors believe that changes in thyroid conditions are related to the balance in the stimulating and blocking activities of antibodies and the thyroid gland's response to these antibodies, causing a pull-push effect shifting either to hypothyroidism or

hyperthyroidism, respectively. A variable behavior of the TRAB with the TSH receptor is responsible for the conversion from hypothyroidism to hyperthyroidism and vice versa. Thyroid damage from an autoimmune phenomenon initially causes thyroid hypofunction, but once enough tissue has recovered, it is stimulated by stimulating antibodies.⁵ Based on the findings of several cases and studies, we diagnosed this patient with HT with Grave's Disease, or we also diagnosed it with Hashitoxicosis.

The patient was given levothyroxine 1x100mg therapy for the condition of hypothyroidism. Hypothyroidism should be treated with thyroid hormone replacement therapy. Initial LT4 dose ranges between 1.4 and 1.8 mcg/kg body weight. On May 17, TSH was 5.97 uIU/mL and FT4 1.34 ng/dL; this indicates a response to the therapy given. The substitution therapy must be taken for life to maintain normal TSH levels.^{1,6,20}

CONCLUSION

A patient with HT diagnosed based on thyroid ultrasound with high anti-TPO was reported. A combination of clinical features and thyroid function tests can help diagnose HT. Based on the patient's clinical and laboratory features, treatment may also be considered.

REFERENCE

1. Ragusa F, Fallahi P, Elia G, et al. Hashimoto's thyroiditis: epidemiology, pathogenesis, clinic and therapy. *Best Pract Res Clin Endocrinol Metab.* 2019;33(6):101367.
2. Mikulska AA, Karazniewicz-Lada M, Filipowicz D, et al. Metabolic characteristics of Hashimoto's thyroiditis patients and the role of microelements and diet in disease management—An overview. *Int J Mol Sci.* 2022;23(12):6592.
3. Hu X, Chen Y, Shen Y, et al. Global prevalence and epidemiological trends of Hashimoto's thyroiditis in adults: A systematic review and meta-analysis. *Front Public Health.* 2022;10:978333.
4. Gonzalez-Aguilera B, Betea D, Lutteri L, et al. Conversion to Graves disease from Hashimoto thyroiditis: a study of 24 patients. *Arch Endocrinol Metab.* 2018;62(6):609–614.
5. Ahmad E, Hafeez K, Arshad MF, et al. Case report: Hypothyroidism conversion to hyperthyroidism: It's never too late. *Endocrinol Diabetes Metab Case Rep.* 2018;2018:18–0044.
6. Klubo-Gwiedzinska J, Wartofsky L. Hashimoto thyroiditis: an evidence-based guide to etiology, diagnosis and treatment. *Pol Arch Intern Med.* 2022;132(3):1–10.
7. Crooks J, Murray IPC, Wayne EJ. Statistical methods applied to the clinical diagnosis of thyrotoxicosis. *Q J Med.* 1959;28:211–234.
8. Billewicz WZ, Chapman RS, Crooks J, et al. Statistical methods applied to the diagnosis of hypothyroidism. *Q J Med.* 1969;38:255–266.
9. Lee SL. Hashimoto thyroiditis. *National Institute of Diabetes and Digestive and Kidney Diseases.* 2014;1–8. [Accessed 2025 Jul 3].
10. Caturegli P, Remigius AD, Rose NR. Hashimoto thyroiditis: clinical and diagnostic criteria. *Autoimmun Rev.* 2014;13(4–5):391–397.
11. Chandanwale SS, Nair R, Gambhir A, et al. Cytomorphological spectrum of thyroiditis: a review of 110 cases. *J Thyroid Res.* 2018;2018:1–7.
12. Bell L, Hunter AL, Kyriacou A, et al. Clinical diagnosis of Graves' or non-Graves' hyperthyroidism compared to TSH receptor antibody test. *Endocr Connect.* 2018;7(4):504–510.
13. Kahaly GJ, Bartalena L, Hegedus L, et al. 2018 European Thyroid Association guideline for the management of Graves' hyperthyroidism. *Eur Thyroid J.* 2018;7(4):167–186.

14. Giovanella L, Avram AM, Iakovou I, et al. EANM practice guideline/SNMMI procedure standard for RAIU and thyroid scintigraphy. *Eur J Nucl Med Mol Imaging*. 2019;46(12):2514-2525.
15. Starrenburg-Razenberg AJ, Cabezas MC, Gan IM, et al. Four patients with hypothyroid Graves' disease. *Neth J Med*. 2010;68(4):178-180.
16. Shrestha A, Adhikari N, Devkota S, et al. Fluctuating hyperthyroidism and hypothyroidism in Graves' disease: the swinging between two clinical entities. *Cureus*. 2022;14(8):e28293.
17. Shahbaz A, Aziz K, Umair M, et al. Prolonged duration of Hashitoxicosis in a patient with Hashimoto's thyroiditis: a case report and review of literature. *Cureus*. 2018;10(6):e2842.
18. Bishay RH, Chen RCY. Hashimoto's thyroiditis and Graves' disease in one patient: the extremes of thyroid dysfunction associated with interferon treatment. *Case Rep Endocrinol*. 2016;2016:1-4.
19. Clifford L, Wakil A. Conversion of primary hypothyroidism to hyperthyroidism. *J ASEAN Fed Endocr Soc*. 2018;33(2):190-193.
20. Ralli M, Angeletti D, Fiore M, et al. Hashimoto's thyroiditis: an update on pathogenic mechanisms, diagnostic protocols, therapeutic strategies, and potential malignant transformation. *Autoimmun Rev*. 2022;21(10):103140.



InaJEMD
 Indonesian Journal of Endocrinology
 Metabolism and Diabetes