

Tertiary Hyperparathyroidism in Patient with End-Stage Chronic Renal Disease

Stella Ilone¹, Em Yunir¹, Alvita Dewi S², Erwin Danil Julian³

1 Endocrinology, Metabolism, and Diabetes Division, Department of Internal Medicine, Cipto Mangunkusumo Hospital

2 Nuclear Medicine Department, Cipto Mangunkusumo Hospital

3 Department of Oncology Surgery, Cipto Mangunkusumo Hospital

*Corresponding author:

Stella Ilone, MD.

Endocrinology, Metabolism, and Diabetes Division, Department of Internal Medicine, Cipto Mangunkusumo Hospital, Jakarta, Indonesia.

Email: stella_ilone@yahoo.com

ABSTRACT

Mineral and bone disorder is frequently associated with chronic kidney disease (CKD) which starts early and worsens with renal progression. This condition depends on calcium and phosphate metabolism which will change parathyroid hormone (PTH) release. Understanding the pathophysiology of both secondary and tertiary hyperparathyroidism can reduce the development of its complications, such as renal osteodystrophy and cardiovascular disease. To describe a case of hypercalcemia patient caused by tertiary hyperparathyroidism with end-stage renal disease (ESRD) who underwent continuous ambulatory peritoneal dialysis (CAPD). A 50-years old patient was consulted for treatment of hyperparathyroidism due to mineral bone disease-related CKD. The patient has high levels of serum calcium, phosphate, and parathyroid hormone levels. She has already taken a phosphate binder and does CAPD 4 times daily. She underwent several radiology tests and knew that there was enlargement of her parathyroid glands. Based on that, she underwent parathyroidectomy with implantation. Until now, we still need to evaluate the changes in serum calcium, phosphate, and PTH level after the surgery. Hyperparathyroidism is a condition related to disturbance in calcium and phosphate homeostasis in CKD patients. Many factors contribute to the development of its progression. Early recognition and holistic treatment will be the most important thing to reduce the complication of hyperparathyroidism in CKD patients.

Keywords: Renal disease, hyperparathyroidism, calcium homeostasis

INTRODUCTION

Hyperparathyroidism (HPT) is a common complication of chronic kidney disease (CKD) characterized with disturbance in calcium, phosphate, and vitamin D homeostasis. It is a condition that is frequently met in patients with chronic kidney disease and the progression depends on patients' renal condition. Renal HPT (rHPT) is classically divided into secondary and tertiary hyperparathyroidism. In secondary HPT, the parathyroid gland will be enlarged caused by hyperplasia of the parathyroid gland. Tertiary HPT develops because of long-standing untreated secondary parathyroid hormone (PTH) and will induce autonomous PTH secretion and hypercalcemia. Serum calcium concentration is the main determinant of PTH release. Patients with CKD have defects in vitamin D activation and will lead to hypocalcemia and hyperphosphatemia. Underlying pathophysiology of HPT becomes more complex, with the activation of several factors, such as fibroblast growth factor (FGF) 23 and Klotho. Several treatments have been established to treat HPT in CKD patients, such as the use of vitamin D analogs, phosphate-binders, calcimimetic drugs, and parathyroidectomy.

METHODS

In this manuscript, we present a case report of a hypercalcemia patient caused by tertiary

hyperparathyroidism with end-stage renal disease (ESRD) who underwent continuous ambulatory peritoneal dialysis (CAPD).

CASE ILLUSTRATION

A 34-years old male patient was consulted by the nephrology division for further work-up of high serum calcium and phosphate level. He has undergone haemodialysis since 2013, 2 times weekly. In 2019 and 2020, he felt pain in his left and right hip. He was diagnosed with bilateral hip fractures. He underwent total hip replacement at his left hip and before he underwent total hip replacement for his right hip, he was consulted to evaluate his parathyroid hormone status. From the nephrology department, he has already done laboratory examinations with increased levels of serum calcium and PTH hormone. He has already consumed sevelamer and vitamin D supplementation. There was no history of diabetes and allergy. He has hypertension and already took some medications.

From the physical examination, we found the patient in good condition. He was fully alert, blood pressure 143/70 mmHg, heart rate and respiratory rates in normal value. He was pale. From the palpation of the neck, we found no thyroid nodules. Other physical examinations were normal.

Table 1. Laboratory results of peri-parathyroidectomy surgery

	4/6/21	27/1/21	17/11/21	25/2/22	10/6/22	6/9/22	25/10/22	7/2/23	10/3/23	Normal value
Hb/Ht/ Lew/Tr						10,4/32/60 90/258.000			11/32/646 0/164.000	
Alb	4,1		3,9	4	4,1	4,2		4,3	4,1	
Ur/Cr			119/9,3 (6,7)	98/10	115/7,4 (8,8)	100,6/5,6 (10,7)		64/9 (69,2)	70,6/-	
Fosfat inorganic	7,1		4,8	4,2	5,7	2,2	3,8	4,3	4,3	2,3-4,7 mg/dl
Ca darah	11,1			8,6	7,89	15	11,6		10,7	8,4-10,2 mg/dL
Ca ion				0,85	1,07	1,55	1,5	1,39		1,01-1,31 mmol/l
Na/K/Cl						133/4,8/96			136/4/101	
Mg	2,4		2,21	2,39	2,5	2,6	2,77			1,67-2,6
iPTH	2308	1480		1878	652,4	10,95	17,25			15-65 pg/ml
Vit D 25(OH)	21,2						17,1			30-100 ng/ml
Alk fosfatase				500	708				67	40-150 U/L

Purple circles showed the time of first and secondary parathyroidectomy surgery. From the parathyroid scintigraphy with MIBI-scan between the second parathyroid surgery showed left inferior parathyroid adenoma with differential diagnosis was parathyroid hyperplasia. Hip x-ray showed there were complete fracture of bilateral hip. Bone mineral densitometry showed low bone density for age (z-score of left wrists joint -2.4).

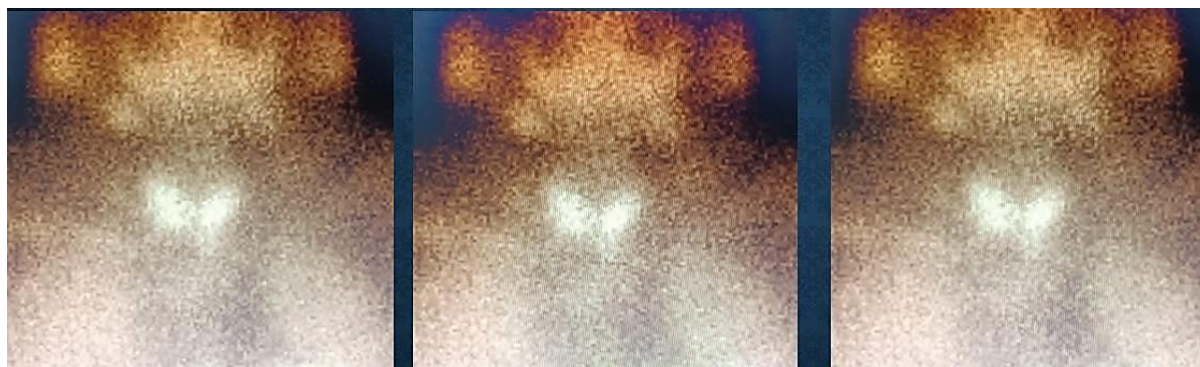


Figure 1. MIBI Scan of the patient before secondary parathyroidectomy

From the laboratory and radiology findings, he was diagnosed with hypercalcemia due to tertiary hyperparathyroidism, CKD stage V on dialysis with renal anemia, hypertension, secondary osteopenia, and closed fracture of bilateral femoral neck. He regularly consumed kolkatriol 2x0.5 mcg, calcium supplementation 3x500 mg, Actonel 35 mg/week, with 3 times HD for every week.

Table 2. Laboratory iPTH Level Perioperatively

	4/6/21	27/7/21	25/2/22	10/6/22	1/7/22	3/8/22	10/9/22	25/10/22	NV
iPTH	2308	1480	1878	652	1662	208	10,95	17,25	15-65 pg/ml

First sPTH
23/6/21

PA: parathyroid adenoma at
upper right, lower right, and
lower left

Secondary iPTH
10/6/22

PA: Histologi sesuai parathyroid
hyperplasia

DISCUSSION

Chronic kidney disease affects a large amount of the world-wide population with impact based on its complications. One of the complications that commonly meet is altered bone metabolism. These biochemical and clinical abnormalities include mineral and bone disorder (CKD-MBD) and renal osteodystrophy (ROD). Mineral and bone disorder refers to the clinical syndrome with mineral, bone, and vascular

calcification abnormalities; whereas ROD refers to the bone pathology of CKD which are found in bone biopsy, such as bone turnover, mineralization, and volume of the bone. The biochemical abnormalities of CKD-MBD begin in CKD stage 3 but have variability in rate and severity. Based on these underlying mechanisms, it is recommended to monitor serum level of calcium, phosphorus, and PTH level in CKD patients.

Parathyroid hormone is a polypeptide protein released by the parathyroid gland and has an essential role in bone mineralization and calcium homeostasis. Free serum calcium concentration is the main determinant of PTH release. Calcium and phosphate homeostasis is maintained through a complex relationship between the bones, intestine, kidneys, and parathyroid gland. Parathyroid hormone plays important roles in calcium metabolism through 3 mechanisms, such as: (1). PTH will stimulate PTH receptors on osteoblasts then stimulate osteoclasts through multiple cell-to-cell mechanisms leading to bone resorption and increased serum calcium and phosphate; (2). PTH activates $1\text{-}\alpha\text{-hydroxylase}$ in the kidney which catalyzes the conversion of inactive 25-hydroxy (25-OH) vitamin D to activated 1,25 dihydroxy-(1,25-OH) $_2$ vitamin D and leads to increased absorption of calcium and phosphate in the gut; (3). PTH increases reabsorption of calcium and decreases reabsorption of phosphate in the kidney.

The development of secondary and tertiary HPT results from many factors, including deficiency of calcitriol, retention of phosphorus, decrease in activation of the calcium-sensing receptor (CaR) in the parathyroid gland, and skeletal resistance to the calcemic effect of PTH. Disturbance in the activation of vitamin D in the kidney can affect serum calcium and phosphate level and result in compensatory increase in parathyroid gland cellularity and PTH production. This is the pathomechanism of secondary hyperparathyroidism in CKD patients. More recently, the underlying pathophysiology has become more complex, with the progressive awareness that fibroblast growth factor 23 (FGF23), a-Klotho (subsequently called "Klotho") as well as the Wnt B-catenin signalling pathway also play an important role in hyperparathyroidism in CKD. FGF-23 stimulates phosphate excretion in the kidney and decreases $1\text{-}\alpha\text{-hydroxylase}$ activity and leads to reduced 1,25-OH vitamin D levels.

Renal HPT, both secondary and tertiary HPT, manifests as one of two types of renal osteodystrophy; either a high turnover state

known as osteitis fibrosa, or, in combination with low bone turnover, known as mixed uremic osteodystrophy. Severe secondary HPT is associated with morbidity and mortality in patients with CKD, especially CKD stage 3-5.

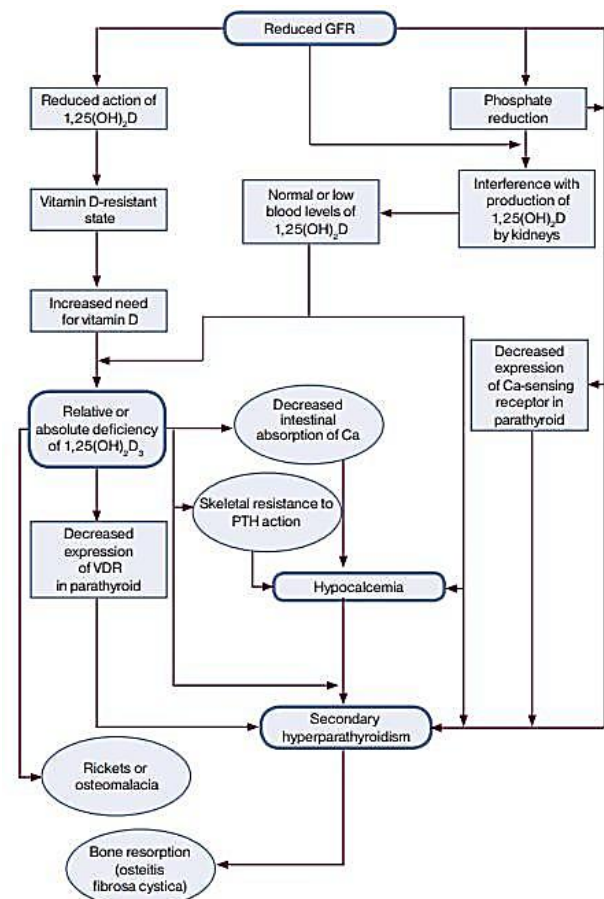


Figure 2. Pathogenesis of mineral metabolism and bone disease in CKD patients

In CKD patients, as the GFR declines, serum phosphate levels start to rise and induce hypocalcemia by binding bioavailable calcium as CaHPO_4 and leads to a further rise in PTH production. Chronic stimulation of the parathyroid gland triggers diffuse polyclonal hyperplasia that leads to development of nodules with loss of negative feedback seen in tertiary HPT.

The other important complication of HPT besides renal osteodystrophy in CKD patients is cardiovascular disease. The abnormalities in calcium and phosphate metabolism may accelerate vascular, including coronary artery calcification. This can affect myocardium, atrial-

ventricular conduction, and valvular function. Some studies have suggested that FGF-23 may induce arterial smooth muscle myocytes to change into osteoblast-like cells that lead to vascular calcification. Based on these underlying mechanisms and other atherosclerotic mechanisms, the morbidity and mortality caused by cardiovascular risk are seen higher in CKD patients.

The management of rHPT follows a stepwise approach with the goal of normal serum phosphate and calcium level. These managements include low phosphate diet, phosphate binders, vitamin D derivatives, calcimimetic medications, and surgery.

Low phosphate diet

Low phosphate diet is recommended in CKD patients with rHPT with hyperphosphatemia. Dietary phosphorus comes from 2 sources, such as protein-rich food groups such as meat and milk and phosphorus additives used to process meat and cheese. Patients with CKD must restrict dietary phosphorus to 800-1000 mg/day.

Phosphate binders

Phosphate binders are an essential part of medical therapy for CKD patients. It is shown to decrease serum phosphate and PTH levels. Several phosphate binders are aluminium hydroxide, calciumsalts, sevelamer hydrochloride, sevelamer carbonate, and lanthanum carbonate. In patients who remain hyperphosphatemic despite initiation of a single phosphate binder, combination therapy can be used.

Vitamin D analogs

Replacement of vitamin D has been shown to be effective in suppressing PTH secretion. Several vitamin D analogs are ergocalciferol (requires activation in the kidney to 1,25-OH vitamin D), active forms of vitamin D such as calcitriol, paricalcitol, and doxercalciferol. If PTH remains elevated or is progressively rising, treatment with calcitriol or vitamin D analogs is suggested. Patients with CKD stage 5 on

dialysis, it is suggested to get active vitamin D sterols such as calcitriol to control HPT.

Calcimimetics

Cinacalcet HCL is a calcimimetic agent that exhibits allosteric modulation of the calcium receptor on the parathyroid gland, increasing sensitivity to extracellular calcium and thereby suppressing PTH secretion. Cinacalcet is shown to lower the rates of fractures and parathyroidectomy.

Surgery

Indication for consideration for parathyroidectomy are: (1) medical management of rHPT > 6 months with hypercalcemia or hyperphosphatemia, PTH > 800 pg/ml, (2) calciphylaxis with documented elevated PTH levels, (3) osteoporosis (T-score >2,5 SD below mean), pathologic bone fracture, (4) symptoms/signs: pruritus, bone pain, severe vascular calcifications, myopathy. There are three most common surgical procedures used in the treatment of rHPT are total parathyroidectomy (TPX) alone, TPX with auto-transplantation, and subtotal parathyroidectomy. In TPX with auto transplantation, all 4 glands are removed followed by autologous reimplantation of 20 mg to 70 mg of the most normal-appearing gland into the sternocleidomastoid muscle, pectoralis major muscle, or forearm brachioradialis muscle. The implantation needs 3 to 4 weeks to revascularize and resume function. Based on long-term prognosis, successful parathyroidectomy can improve symptoms, like bone pain, arthralgia, muscle weakness, and psychological disturbances. Long-term relative risks of death are reduced by 10-15%.

CONCLUSION

Renal hyperparathyroidism is one of the common complications in CKD patients. Morbidity and mortality associates with disturbance in serum calcium and phosphate level which correlates with osteodystrophy renal and cardiovascular risk in CKD patients. Early recognition and treatment to normalize calcium,

phosphate, and PTH level will reduce the risk of hyperparathyroidism, both secondary and tertiary.

REFERENCES

1. Moe SM, Drüeke T, Lameire N, Eknoyan G. Chronic kidney disease-mineral bone disorder: a new paradigm. *Adv in Chronic Kid Dis*. 2007;14:3-12.
2. Uhlig K, Berns JS, Kestenbaum B, et al. KDOQI U.S. commentary on the 2009 KDIGO clinical practice guideline for the diagnosis, evaluation, and treatment of chronic kidney disease-mineral and bone disorder (CKD-MBD). *Am J Kidney Dis*. 2010;55:773-799.
3. Felsenfeld A, Silver J. Pathophysiology and clinical manifestations of renal osteodystrophy. In: Olgaard K, ed. *Clinical guide to bone and mineral metabolism in CKD*. New York, NY: National Kidney Foundation; 2006:31-41.
4. Ketteler M, Petermann AT. Phosphate and FGF 23 in early CKD: on how to tackle an invisible foe. *Nephrol Dial Transplant*. 2011;26:2430-2.
5. Kidney Disease Outcomes Quality Initiative (KDOQI). KDOQI clinical practice guidelines for bone metabolism and disease in chronic kidney disease. *Am J Kidney Dis*. 2003;42(suppl 3):S1S170.
6. Ho LY, Wong PN, Sin HK, Wong YY, Lo KC, et al. (2017) Risk factors and clinical course of hungry bone syndrome after total parathyroidectomy in dialysis patients with secondary hyperparathyroidism. *BMC Nephrol* 18: 12.
7. Boeckler P, Grunenberger F, Ruellan A, Vignon F, Weber JC, et al. (2002) Hungry bone syndrome after surgical treatment of severe primary hyperparathyroidism: about 3 cases. *Ann Endocrinol* 63: 8-12.
8. Brasier AR, Nussbaum SR (1988) Hungry bone syndrome: clinical and biochemical predictors of its occurrence after parathyroid surgery. *Am J Med* 84: 654-660.
9. Mittendorf EA, Merlino JI, McHenry CR (2004) Post-parathyroidectomy hypocalcemia: incidence, risk factors, and management. *Am Surg* 70: 114-119.
10. van der Plas WY, Vogt L, Kruijff S: Advances in the diagnosis and management of secondary and tertiary hyperparathyroidism. In: Shifrin A (Ed.) *Advances in Treatment and Management in Surgical Endocrinology*. Elsevier Inc, Amsterdam, 2019, p. 326.



InaJEMD
Indonesian Journal of Endocrinology
Metabolism and Diabetes