

## Detection of Small Lesion Insulinoma with $^{68}\text{Ga}$ -DOTATATE PET/CT scan: A Case Report

Irma Wahyuni<sup>1</sup>, Tri Juli Edi Tarigan<sup>1</sup>, Hendra Budiawan<sup>2</sup>, Alvita Dewi<sup>3</sup>, Rian Hidayatullah<sup>3</sup>, Hasan Maulahela<sup>4</sup>

- 1 Division of Metabolic, Endocrine and Diabetes, Departement Internal Medicine, Cipto Mangunkusumo Hospital, University of Indonesia, Jakarta.
- 2 Department of Nuclear Medicine, Hasan Sadikin Hospital, Padjadjaran University, Bandung, Jawa Barat
- 3 Department of Nuclear Medicine, Cipto Mangunkusumo Hospital, University of Indonesia, Jakarta
- 4 Division of Gastroenterology, Pancreticobillier and Digestive Endoscopy, Departement Internal Medicine, Cipto Mangunkusumo Hospital, University of Indonesia, Jakarta

\*Corresponding author:

Irma Wahyuni, MD.

Division Endocrinology, Metabolism, and Diabetes, Department of Internal Medicine, Cipto Mangunkusumo Hospital, Jakarta, Indonesia.

Email: irma\_dr@yahoo.com

### ABSTRACT

Endogenous hyperinsulinism is a rare condition characterized by inappropriate insulin secretion, with insulinoma accounting for approximately 55% of cases. A 36-year-old woman presented with recurrent hypoglycemic episodes for 4.5 years, particularly in the morning, relieved by glucose intake. Laboratory findings during a supervised fasting test revealed a blood glucose of 44 mg/dL, elevated insulin (15  $\mu\text{U/mL}$ ), C-peptide (2.27 ng/mL), proinsulin (53.1 pmol/L), and suppressed beta-hydroxybutyrate (0.1 mmol/L), indicating endogenous hyperinsulinemia. Initial imaging modalities including CT, MRI, and EUS failed to localize the lesion. The patient discontinued investigation but resumed a year later with nuclear imaging studies. A  $^{99\text{mTc}}$ -HYNIC-TOC scan was inconclusive, but subsequent  $^{68}\text{Ga}$ -DOTATATE PET/CT at Hasan Sadikin Hospital revealed a somatostatin receptor-expressing nodule at the pancreatic head, consistent with insulinoma. Given the lesion's location and imaging findings, treatment options were discussed, including Whipple's procedure versus radiofrequency ablation. Insulinomas are typically small, with 80% under 2 cm and 40% under 1 cm, often making localization challenging. While CT and MRI have detection rates of 70% and 86% respectively, the combination of CT and EUS may reach 100% sensitivity. In cases where conventional imaging is inconclusive,  $^{68}\text{Ga}$ -DOTATATE PET/CT provides a valuable alternative, capable of detecting neuroendocrine tumors as small as 6 mm. This case highlights the critical role of nuclear medicine in localizing elusive insulinomas and guiding definitive treatment.

**Keywords:** hypoglycemia, insulinoma,  $^{68}\text{Ga}$ -DOTATATE PET/CT scan

## INTRODUCTION

Insulinoma is the most common pancreatic F-NET, arising from beta islet cells that secrete insulin and is associated with hypoglycemia neuroglycopenia and sympathetic overstimulation. Most are benign and well differentiated NETs. Insulinomas are rare functional neuroendocrine tumours (NETs) of the pancreas. The majority of insulinomas are small, measuring less than 2 cm. Despite their small size, insulinomas are the most common functional neuroendocrine tumours. Although mostly sporadic, up to 10% may be associated with hereditary multiple endocrine neoplasia type I (MEN-1).<sup>1</sup> The challenges of insulinoma diagnosis, localisation and surgical management have changed over the last few decades. Once the biochemical diagnosis of an insulinoma is established, localisation procedures are performed. Due to their small size (82% <2 cm and 47% <1 cm), insulinomas are difficult to localise with current imaging techniques.<sup>2,3</sup> Accurate preoperative localization of an insulinoma is desirable because some tumors may not be palpable at the time of surgery. Several studies have shown that when <sup>68</sup>Ga-labelled somatostatin analogue PET is combined with CT, the sensitivity for detecting neuroendocrine tumors is higher than with SSTR scintigraphy. A meta-analysis study suggested that <sup>68</sup>Ga-DOTATATE is the most accurate for detecting neuroendocrine tumours.<sup>3</sup> Although the importance of this

examination is for finding especially for small lesion insulinoma, but this modalities not yet available in every nuclear medicine facilities in Indonesia.

## CASE REPORT

A 36-year-old woman has had recurrent episodes of hypoglycemia for 4.5 years. The first symptoms are recognized when the patient hardly gets out of bed in the morning, accompanied by heavy sweating. After a glass of sweet tea, the patient regains consciousness. No seizure is reported. The patient often eats every 4-6 hours to overcome the symptoms of hypoglycemia, resulting in an increase in her body weight of about 25 kilos in 4.5 years. There is no history of taking herbs or other routine medications that could potentially cause hypoglycemia. A laboratory test shows an FBG of 45 mg/dL. The patient then goes to the endocrinologist and a prolonged fasting test concludes that the patient has endogenous hyperinsulinemia, where are at BG 44 mg/dL, the C-Peptide 2.27 ng/mL, insulin level at 15 µIU/mL, proinsulin level at 53.1 pmol/L and beta-hydroxybutyrate 0.1 mmol/L. The patient has undergone several imaging studies, from abdominal ultrasound to abdominal MRI, but without satisfactory results. EUS has also been performed but shows no specific findings. Patient feels disappointed and does not seek further opinion.

Figure 1. Prolonged fasting test result<sup>4</sup>

Examination	Patient result	Diagnosis criteria for Endogenous Hyperinsulinemia		Normal lab reference
		Western	Chinnesse large cohort study	
End of fast glucose	44 mg/dL	< 3 mmol/L ( < 54 mg/dL)	< 2,8mmol/L ( < 50mg/dL)	60 -140 mg/dL
Insulin	15 µIU/mL	> 3 µIU/mL	> 5.5	2 – 25 µIU/mL
β-hydroxybutyrate	0,1 mmol/L			< 0,6 mmol/L
C-peptide	2,27 ng/mL	> 0.6 ng/mL	> 0,9 ng/mL	0,78 – 5,19 ng/mL
Proinsulin	53,1 pmol/L	>= 5	>= 12	<= 18,8 pmol/L

After 1 year, the patient decided to restart the investigation and a nuclear medicine scan was scheduled. At first a <sup>99m</sup>Tc Hynic TOC examination is performed but shows no typical neuroendocrine tumour in pancreas or

other organ, and then after waiting for several months a <sup>68</sup>Ga-DOTATATE PET/CT was performed in Hasan Sadikin Hospital and result shows a nodule at head of pancreas surrounding pancreaticoduodenal junction that

expresses somatostatin receptor, suggesting an insulinoma. A meeting was done and the definitive treatment option are between Whipple's procedure or radiofrequency ablation (RFA). An RFA was chosen after family meeting held with team.

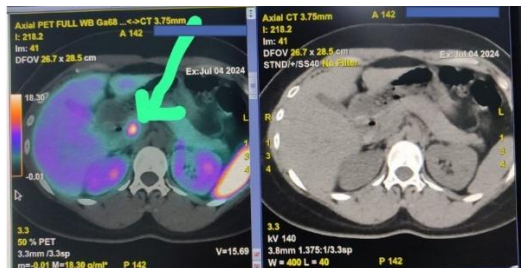


Figure 2. a  $^{68}\text{Ga}$ -DOTATATE PET/CT shows suggestive a insulinoma at head of pancreas

## DISCUSSION

Although insulinoma is a rare endocrine disorder, it is the most common cause of hypoglycemia in apparently healthy adults when

factitious hypoglycemia is excluded. As insulinomas occur in the pancreas in the majority of patients, the pancreas is the first site to be investigated. A variety of symptoms have been described in patients presenting with this tumour.<sup>5</sup> Unfortunately, only 53% of patients are diagnosed within 5 years of their first symptom.<sup>1</sup> Spontaneous hypoglycemia from insulinoma can cause neuroglycopenic symptoms. Patients typically present with neurological symptoms such as confusion, dizziness, behavioral changes and may be accompanied by weight gain with normal thyroid function.<sup>1</sup>

Table 1. Frequent symptoms of insulinoma<sup>1</sup>

Neuroglycopenic symptoms	Adrenergic symptoms
Confusion (80%)	Diaphoresis (69%)
Visual disturbances (59%)	Tremors (24%)
Amnesia or coma (47%)	Palpitations (12%)
Abnormal behavior (36%)	Hyperphagia/weight gain (50%)
Seizures (17%)	

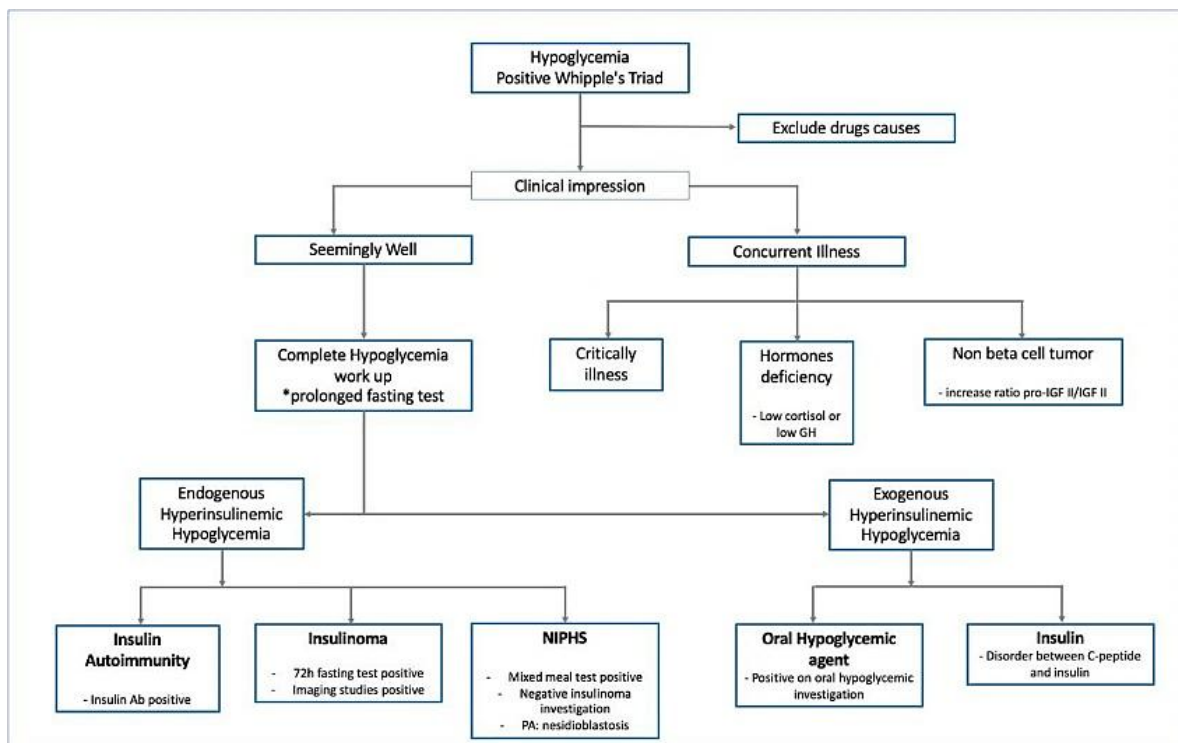


Figure 3. Algorithm for evaluating hypoglycemia in adult (modified from Marten et al)<sup>6</sup>

Once a high clinical suspicion for an insulinoma is confirmed, biochemical tests based on prolonged monitored fasting are performed to confirm the diagnosis. The 72-hour monitored fast has been the gold standard

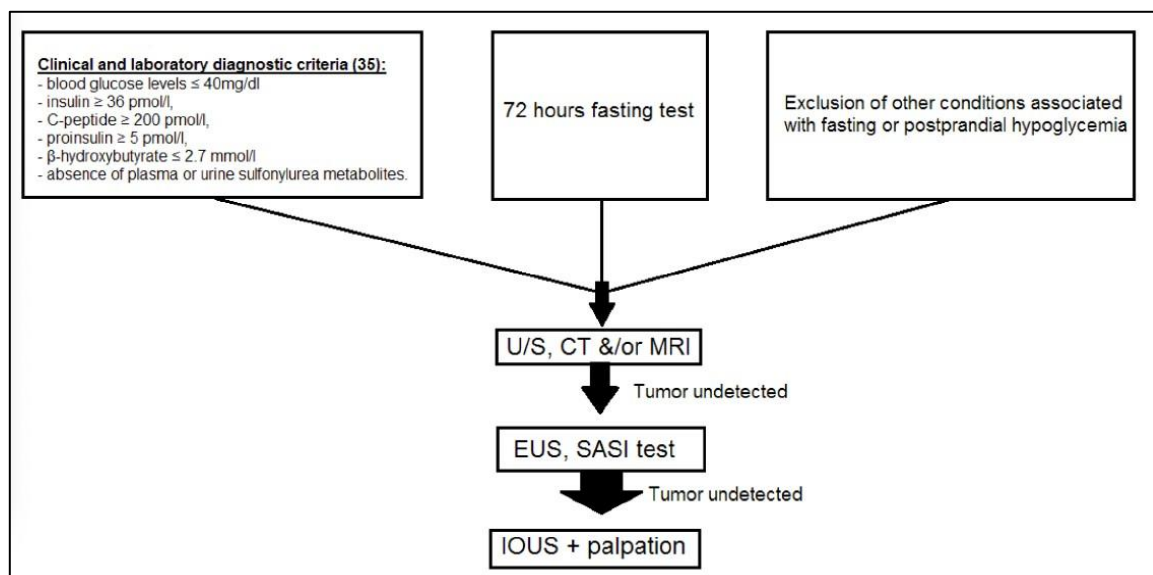
for the diagnosis of this tumor for over 80 years. The protocol involves measuring the levels of plasma glucose, insulin, C-peptide and proinsulin in the same sample and repeating the measurements every 6 hours until the plasma

glucose level is 58 mg/dL; the fast is terminated either when the plasma glucose level is 45 mg/dL or the patient has signs and symptoms of hypoglycaemia.<sup>1</sup> Biochemical abnormalities of insulinoma may be seen in other conditions associated with fasting hypoglycemia or postprandial hypoglycemia, so other causes should be ruled out first.<sup>7</sup>

**Table 2. Differential diagnosis of hypoglycemia<sup>7</sup>**

Oral hypoglycemics (sulfonylureas, meglitinides)
Exogenous insulin administration
Systemic conditions (renal failure, liver failure, sepsis, non-pancreatic malignancies, adrenal insufficiency)
Autoimmune disease (SLE)
Multiple myeloma
Post-gastric bypass hypoglycemia
NIPHS

When the biochemical diagnosis of an insulinoma is confirmed, the next step is preoperative localization. The most effective method of locating insulinomas is still controversial, as both preoperative and intraoperative approaches have been advocated. Preoperative localization of insulinomas can be non-invasive or invasive. Non-invasive imaging modalities include abdominal ultrasonography, bolus enhanced helical computed tomography (CT), magnetic resonance imaging (MRI) and somatostatin receptor scintigraphy. Invasive studies include selective angiography, transhepatic portal vein sampling, endoscopic ultrasound (EUS) and selective arterial calcium stimulation (SACS). Some suggest that the combination of surgical exploration and IOUS can identify more than 90% of insulinomas.<sup>1</sup> These are stepwise suggestion in diagnosing insulinoma.



**Figure 4. Algorithm for the diagnosis and localization of insulinomas<sup>7</sup>**

In this case, A series of stepwise imaging procedures were conducted after biochemical diagnosis were confirmed, including abdominal ultrasound, CT scan, MRI and EUS, but these did not yield a satisfactory result for locating the lesion. After the patient underwent a <sup>68</sup>Ga-DOTATATE PET/CT scan, this examination enabled the location of the lesion to be determined, which was found in the head of the pancreas in the vicinity of the pancreatico-

duodenal junction. The diameter of the lesion was measured at 11 mm.

It has previously been reported that <sup>68</sup>Gallium DOTATATE PET/CT scan can detect NETs as small as 6 mm.<sup>8</sup> In a study comparing different imaging modalities for the localisation of insulinomas, the accuracy of <sup>68</sup>Gallium DOTATATE PET/CT scan was around 90% compared to CT (55%), MRI (61%) and US (21%).<sup>8</sup> The <sup>68</sup>Gallium DOTATATE PET/CT scan has a

high affinity for somatostatin receptor 2 (SSTR2), which is commonly expressed in NETs. This SSTR2 expression in insulinomas is present in up to 80% of cases.<sup>9</sup> Although Selective Arterial Secretagogue Injection (SASI) is more accurate for regionalizing insulinomas, it's a costly and invasive test that requires a skilled interventional radiologist, who may not be readily available, and it can be associated with complications. A <sup>68</sup>Ga-DOTATATE has been shown to be safe with a lower total radiation exposure than <sup>18</sup>F-FDG.<sup>8</sup>

## CONCLUSION

Due to their small size, the localization of insulinomas is challenging. Imaging with <sup>68</sup>GaDOTATATE PET/CT may be an alternative imaging modality for patients with negative results from other non-invasive radiological localization studies. Availability of this modality in Indonesia would be another issue.

## REFERENCE

1. Libutti, S. & Taye, A. Diagnosis and management of insulinoma: current best practice and ongoing developments. *Res. Reports Endocr. Disord.* 125 (2015) doi:10.2147/rred.s86565.
2. SERVICE, F. J., McMAHON, M. M., O'BRIEN, P. C. & BALLARD, D. J.
3. Functioning Insulinoma—Incidence, Recurrence, and Long-Term Survival of Patients: A 60-Year Study. *Mayo Clin. Proc.* 66, 711-19 (1991).
4. Tuzcu, S. A., Pekkolay, Z., Kilingç, F. & Tuzcu, A. K. <sup>68</sup>Ga-DOTATATE PET/CT can be an alternative imaging method in insulinoma patients. *J. Nucl. Med. Technol.* 45, 198-200 (2017).
5. Yu, J. et al. The optimal diagnostic criteria of endogenous hyperinsulinemic hypoglycemia based on a large cohort of Chinese patients. *Front. Endocrinol. (Lausanne)*. 13, 1-7 (2022).
6. Ahn, C. H. et al. Clinical implications of various criteria for the biochemical diagnosis of insulinoma. *Endocrinol. Metab.* 29, 498-504 (2014).
7. Martens, P. & Tits, J. Approach to the patient with spontaneous hypoglycemia. *Eur. J. Intern. Med.* 25, 415-21 (2014).
8. Giannis, D. et al. Insulinomas: From diagnosis to treatment. A review of the literature. *J. B.U.ON.* 25, 1302-14 (2020).
9. Nockel, P. et al. Localization of insulinoma using <sup>68</sup>Ga-DOTATATE PET/CT scan. *J. Clin. Endocrinol. Metab.* 102, 195-9 (2017).
10. Prasad, V. et al. Role of <sup>68</sup>Ga somatostatin receptor PET/CT in the detection of endogenous hyperinsulinaemic focus: an explorative study. *Eur. J. Nucl. Med. Mol. Imaging* 43, 1593-1600 (2016).



**InaJEMD**  
Indonesian Journal of Endocrinology  
Metabolism and Diabetes