
CASE REPORT

A 59-year-old man with Riedel's Thyroiditis, Initial Suspicion of Thyroid Cancer and Improved with Tamoxifen and Corticosteroid Therapy

Ika Hudayani^{1*}, Himawan Sanusi¹

1 Division of Endocrine Metabolism and Diabetes Mellitus, Faculty of Medicine, Wahidin Sudirohusodo Hospital, Universitas Makassar

**Corresponding author:*

Ika Hudayani, MD.

Department of Internal Medicine, Faculty of Medicine, Universitas Hasanuddin, Makassar, Indonesia.

Email: ikahudayani.ih@gmail.com

ABSTRACT

Riedel's thyroiditis is a rare fibrotic condition involving damage to the thyroid gland and infiltration of surrounding structures. Synonyms of Riedel's thyroiditis include Riedel's goiter, fibrous goiter, ligneous goiter, or chronic invasive fibrous thyroiditis. The inflammatory thyroid condition of Riedel's thyroiditis is a local manifestation of a systemic fibrous or autoimmune process and chronic sclerosis or productive thyroiditis. A 59-year-old man came to the Endocrinology Clinic at Wahidin Sudirohusodo Hospital and was consulted by an oncology surgeon colleague with complaints of a lump in his neck for 2 years before coming to the hospital. Initially the lump was the size of a marble then it got bigger, felt hard, and not painful. The patient had a history of biopsies by surgical colleagues 2 times, the first in May 2022 Fine Needle Aspiration Biopsy with Malignancy (Papillary) results at Bhayangkara Hospital, then the patient was referred to a surgical oncology colleague at Wahidin Sudirohusodo Hospital and a 1-month incision biopsy was performed before going to the endocrine polyclinic with the results of Riedel's Thyroiditis. The patient was then given therapy with Tamoxifen 20 mg per 24 hours orally, and Methylprednisolone 16 mg per 8 hours orally with tapering doses every 7 days. In the treatment during control there were no complaints but complaints of a lump in the neck tended to shrink so the treatment was continued for 2 months then the patient returned to control with a clinical lump in the neck shrinking (Improvement). Riedel's thyroiditis is a disease characterized by an overgrowth of connective tissue that can invade surrounding structures. This connective tissue growth may extend into the recurrent laryngeal nerve. This thyroid inflammatory condition is suspected as a local manifestation of a systemic fibrotic process or an autoimmune process. Commonly used therapies such as glucocorticoids and immunosuppressant agents such as tamoxifen. Steroid treatment is usually given at a dose of 100 mg of prednisolone daily.

Keywords: *Riedel's thyroiditis, tamoxifen, prednisolone*

INTRODUCTION

Riedel's thyroiditis is a rare fibrotic condition involving damage to the thyroid gland and infiltration of surrounding structures. Synonyms of Riedel's thyroiditis include Riedel's goiter, fibrous goiter, ligneous goiter, or chronic invasive fibrous thyroiditis.^{1,2} The inflammatory thyroid condition of Riedel's thyroiditis is a local manifestation of a systemic fibrous or autoimmune process and chronic sclerosis or productive thyroiditis. This condition is characterized by progressive overgrowth of fibrous connective tissue that can invade structures around the thyroid so it most often presents with obstructive symptoms such as dyspnea, dysphagia, and hoarseness. Riedel thyroiditis may also present with manifestations of hypothyroidism, hypoparathyroidism, or Horner's syndrome.^{2,3}

Riedel's thyroiditis is an extremely rare condition with an estimated incidence of 1.06 per 100,000 population and approximately 0.06% thyroidectomy.³ In a meta-analysis it was stated that the average age of Riedel Thyroiditis patients was 47 years with the majority being women (81%). The most common ethnicity found was Caucasian followed by Asian. The majority of patients had experienced hypothyroidism (46%) or euthyroidism (44%). The remainder had hyperthyroidism (7%), subclinical hypothyroidism (2%), or subclinical hyperthyroidism (1%).⁴

The cause of Riedel's thyroiditis is not known. This disease is associated with systemic fibrotic processes and autoimmune diseases. It was recently stated that Riedel's thyroiditis is associated with high levels of immunoglobulin G type 4 (IgG4).^{2,3,5,6} The diagnosis of Riedel's thyroiditis usually requires histopathological confirmation that there is a fibroinflammatory process of the thyroid with extension to the surrounding tissues. Inflammatory infiltrate, lymphoid follicles, granulomatous changes. Treatment of Riedel's thyroiditis is primarily aimed at reducing inflammation. Drugs such as steroids and immunosuppressant agents such as tamoxifen and mycophenolate mofetil are used to treat Riedel's thyroiditis. Surgery is

sometimes needed for cases with obstructive symptoms.^{4,5}

CASE REPORT

A 59-year-old man came to the Endocrine Clinic at Wahidin Sudirohusodo Hospital and was consulted by an oncology surgeon colleague with complaints of a lump in his neck 2 years before coming to the hospital. Initially, the lump was the size of a marble then it got bigger, felt hard, no pain. No fever, no history of fever. No weight loss. Weakness does not exist. There is no swallowing pain, no difficulty swallowing, no coughing and shortness of breath. There is no hoarseness. No chest pain, no abdominal pain. no nausea and vomiting. Urinate smoothly, clear yellow, no pain, no blood, smooth defecation, soft solid consistency, brownish, no blood. There is a history of hypothyroidism 2 years ago and had received levothyroxine 100mcg/24hours/oral but stopped because thyroid function tended to be normal in the last 1 month. History of biopsy by surgeon colleagues for the first 2 times in May 2022 Fine Needle Aspiration Biopsy with Malignancy (Papillary) results at Bhayangkara Hospital then the patient was referred to an oncology surgeon colleague at Wahidin Sudirohusodo Hospital and an incision biopsy was performed 1 month before going to endocrine polyclinic with Riedel Thyroiditis results. There was no history of hypertension and diabetes mellitus. There is no family history of similar complaints. There was no history of smoking or consumption of alcoholic beverages.

On physical examination, the general condition looked moderately ill, with adequate nutrition, compost mentis. Blood pressure 120/70 mmHg, pulse 72 times/minute, regular and lifting strength, respiratory rate 20 times/minute, axillary temperature 36.70 C. Body weight 64 kg and height 169 cm with body mass index 22.4 kg/m².

On physical examination of the head, it was found to be normocephalic, partly gray hair, not easily removed. The conjunctiva is not pale, the sclera is not icteric. There is no palpebral edema. The neck looks like a surgical scar,

palpable thyroid mass measuring about 11x6x12cm, feels hard, immobile, not hyperemic, with no tenderness, no warmth. Palpable multiple enlargement of supraclavicular and paracervical lymph nodes, average size of about 0.5x0.5cm, painless, rubbery consistency. On thoracic examination, venous dilatation was seen, symmetrical, right and left vocal fremitus were the same, right and left resonant percussion, vesicular breath sounds, no crackles and wheezing, no stridor. On examination, the ictus cordis was not visible and could not be felt, the heart border was normal. Single regular first and second heart sound, no murmurs. On abdominal examination, the abdomen looked flat, followed by breathing movements, and normal peristalsis. The liver was not palpable, the spleen was not palpable, there was no tenderness. There are no ascites. On examination of the warm acral extremities, edema is absent.

Based on the history and physical examination, the patient had clinical symptoms of Riedel's thyroiditis, so further examination was carried out. Patients underwent laboratory investigations, radiological and histopathological examinations.

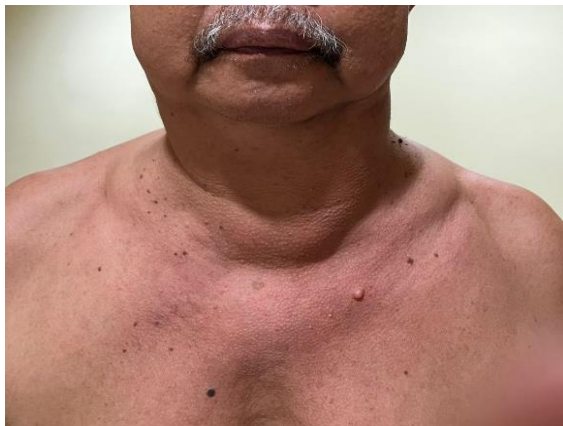

Figure 1. Clinical photo of the patient before treatment

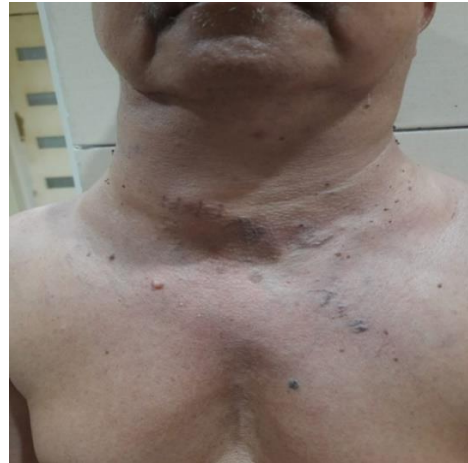

Figure 2. Clinical photos of the patient after treatment with methylprednisolone and tamoxifen

Soft tissue density is seen in the colli region bilaterally which has entered the superior thoracic aperture. Soft tissue density in the paratracheal area is well defined, the edges are regular, form an obtuse angle to the lungs, and a is within clean houte sign to the ascending aorta. The heart normal CTR, dilated aorta. Both sinuses and diaphragm are good, and bones are intact. From this examinations, we found bilateral soft tissue masses in the neck a superior mediastinal mass presumed to be a thymoma, and aortic dilatation.

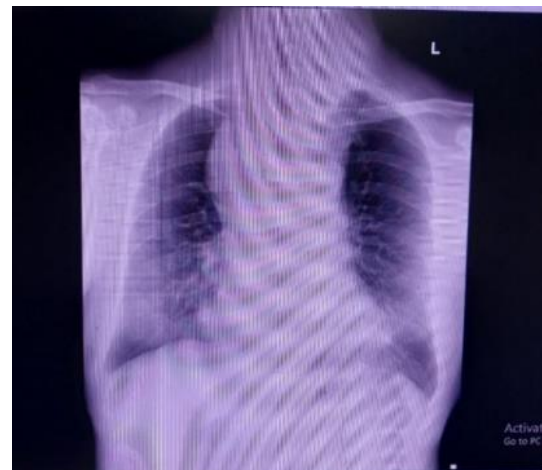

Figure 3. Photo of the patient's chest

Table 1. Laboratory Examination Results at Wahidin Sudirohusodo Hospital

Routine Blood	03-06-2022	Reference Value
WBC	6,000	4-10 x 103/ul
Neutrophils	61.2	52-75 %
Lymphocytes	27.1	20-40 %
Monocytes	5.8	2-8 103/ul
Eosinophils	5.4	1-3 103/ul
Basophils	0.5	0-0.1 103/ul
Hemoglobin	14.3	12-16 gr/dl
MCV	94	80-97 fL
MCH	30	26.5-33.5 p.m
PLT	271,000	150-400 x 103/dl
PT	10,7	10-13 sec
APTT	24.8	25-35
INR	1.03	<1.10

Blood Chemistry	03-06-2022	Reference Value
SGOT	24	<37 U/L
SGPT	18	<42U/L
UREUM	22	10-50 mg/dl
creatinine	1.14	<1.3 mg/dl
GDS	87	<110 mg/dl
Albumin	3.6	3.8 - 5.1 g/dl
FT4	1.45	0.93 - 1.71 ng/dl
TSHs	2.28	0.27 - 4.20 mIU/ml
Sodium	143 mmol/ltr	136-145 mmol/ltr
Potassium	4.0 mmol/ltr	3.5-5.5 mmol/ltr
Cloride	106 mmol/ltr	94-110 mmol/ltr

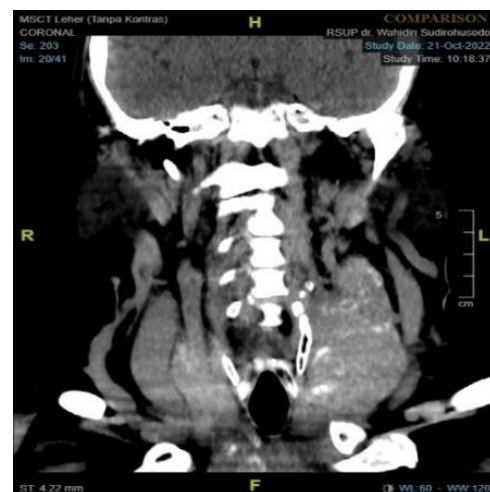
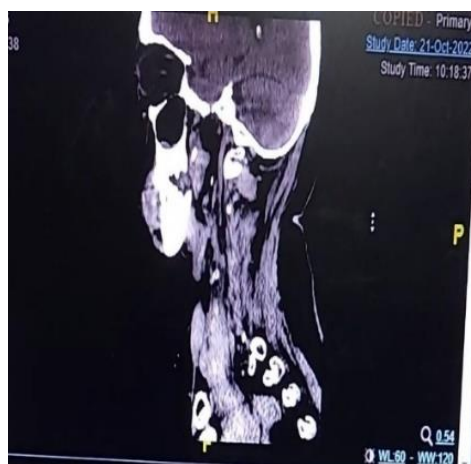
Figure 4. MSCT of the patient's neck

The right thyroid was enlarged with irregular margin, and increased and heterogeneous tissue density, along with multiple calcifications in the parenchyma. The left thyroid showed an enlarged size with irregular margin, increased tissue density, and heterogeneous, multiple calcifications in the parenchyma. There were multiple enlargements accompanied by calcification in the lymph nodes in the submandibular region level IIa, level IIb, level III and IV paracervical region, level V supraclavicular region, and bilateral thoracic level paratracheal. Bilateral parotids were enlarged, especially on the right, with irregular edges, and decreased parenchymal density. The nasopharynx area appeared symmetrical, the parapharyngeal space and larynx appeared normal. The fossa of Rosenmüller was good. Both piriform sinuses appeared normal. The scanned paranasal sinuses and mastoid air cells were within normal limits. Scanned cerebral parenchyma within normal limits, without any impaired bores. The imaging revealed features consistent with chronic thyroiditis, accompanied by multiple lymphadenopathies in the submandibular region (levels IIa and IIb), paracervical region (levels III and IV), supraclavicular region (level V), and bilateral paratracheal regions within the thorax. Additionally, a bilateral thyroid mass is observed, along with suspected bilateral parotid gland enlargement.

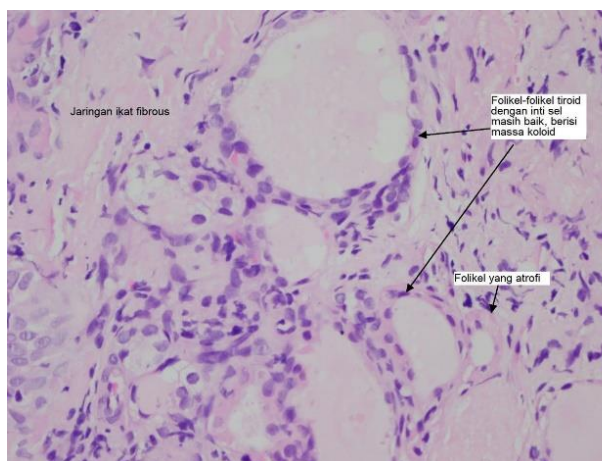


Figure 5. Histopathology

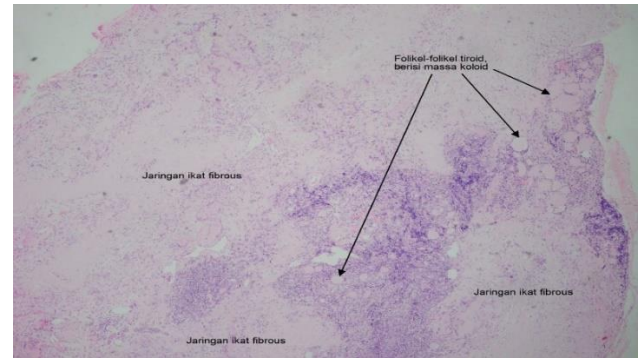


Figure 5. Histopathology

Examination of the thyroid revealed brownish-white tissue with a dense, and chewy consistency macroscopically. Microscopely, atrophic thyroid follicles with distinct nuclei were observed, some contained collards, and were surrounded by inflammatory lymphocytes and fibrous connective tissue.

The patient was diagnosed with Riedel's Thyroiditis. The patient was given therapy with Tamoxifen 20 mg per 24 hours orally, and Methylprednisolone 16 mg per 8 hours orally with tapering doses every 7 days. In the treatment during control there were no complaints but complaints of a lump in the neck tended to shrink so that treatment was continued for 2 months then the patient returned to control with a clinical lump in the neck shrinking.

DISCUSSION

A 59-year-old man with Riedel's Thyroiditis was consulted by a surgical oncology colleague with a diagnosis of Riedel's Thyroiditis, complaints of tumor et regio colli which tended to get bigger for 2 years before going to the hospital, hard consistency but not painful. Riedel's thyroiditis is a disease characterized by an overgrowth of connective tissue that can invade surrounding structures. This connective tissue growth may extend into the recurrent laryngeal nerve. This thyroid inflammatory condition is suspected as a local manifestation of a systemic fibrotic process or an autoimmune process.^{5,7} It has recently been recognized that Riedel's thyroiditis may occur as part of a systemic disease associated with IgG4. IgG4-associated systemic

disease is defined as IgG4 plasma cell infiltration and fibrosis.^{5,8}

The hallmark of Riedel's thyroiditis is the replacement of thyroid tissue with dense fibrotic tissue. Fibrosis can involve extrathyroidal structures, including the trachea, parathyroid glands, neck muscles, laryngeal nerves, and blood vessels. Clinically, the physical examination revealed a thyroid tumor with a firm consistency.¹

Radiological examination can be used in making the diagnosis of Riedel's Thyroiditis. Computed Tomography (CT) scan and nuclear magnetic resonance (NMR) show extensive fibrosis of the thyroid parenchyma in the form of a heterogeneous appearance, either hypodense or isodense. This patient was found to be enlarged in size, with irregular margins, with increased tissue density and heterogeneous, with multiple calcifications in the parenchyma. The advantage of CT and NMR is that they can assess the extent of the spread of Thyroiditis to surrounding tissues, including the possibility of vascular invasion.^{5,9,10}

Most patients have normal thyroid function, and both TSH and Free T4 are normal in most of those affected. However, many patients are also reported to have hypothyroidism. In a meta-analysis, 46% of individuals had experienced a phase of hypothyroidism before the disease process.^{4,5}

This patient has a history of hypothyroidism and has received therapy for 2 years but currently the results of thyroid function tests are within normal limits. The diagnosis can be confirmed on histological examination. The results of fine needle aspiration (FNAB) cannot be used as a benchmark and surgical biopsies are more reflective of the histological results of Riedel's thyroiditis. The histopathological diagnosis is confirmed by the characteristic features of a fibroinflammatory process in the thyroid with extension into the surrounding tissues, an inflammatory infiltrate that does not contain giant cells, lymphoid follicles, oncocytes, or granulomas, evidence of occlusion; and no evidence of thyroid malignancy.^{4,5,10} In this case, an incisional

biopsy was performed by a surgical oncology colleague and an evaluation of the confirmation of histopathological results was carried out by an anatomical pathology colleague, with the same results as the histopathological diagnosis of Riedel's Thyroiditis.

Currently, there are no guidelines or large-scale clinical studies that discuss the optimal management of Riedel's thyroiditis. This is due to the low incidence of Riedel's Thyroiditis. Therapy should aim to treat hypothyroidism in those who present it and manage life-threatening fibrosclerotic manifestations such as airway compression.⁵ Commonly used therapies such as glucocorticoids and immunosuppressant agents such as tamoxifen. Steroid treatment is usually given at a dose of 100 mg of prednisolone daily.

A rapid response to steroid treatment is found in most cases. However, relapse of symptoms is also common and may occur when the dose is reduced. In addition to steroids, tamoxifen is also used in monotherapy or as an adjunct when steroids fail. Tamoxifen has an anti-inflammatory role through the induction of autocrine secretion that converts growth factor $\beta 1$. These drugs can relieve symptoms and reduce the size of the mass. The dose of tamoxifen used is between 10 and 20 mg daily. Mycophenolate mofetil has also been reported to have been used to treat Riedel's thyroiditis in cases resistant to steroids and tamoxifen.^{4,10} This patient was given therapy with Tamoxifen 20 mg/24 hours orally, and Methylprednisolone 16 mg/8 hours orally with tapering doses every 7 days. In the treatment during control there were no complaints but complaints of a lump in the neck tended to shrink so the treatment was continued for 2 months later the patient returned to control with a clinical lump in the neck shrinking.

Definitive treatment with surgical management is sometimes required in cases complicated by obstructive symptoms. In this case, surgical management was not carried out because it did not yet show obstructive symptoms. The prognosis of most patients improves or remains stable with medical and

surgical management. In a meta-analysis is also found a better prognosis, with 90% having improvement or resolution of symptoms but needing an average monitoring of 12 months.^{4,11}

CONCLUSION

A case of Riedel's thyroiditis was reported in a man aged 59 years. Complaints improved after getting Tamoxifen and methylprednisolone therapy for 2 months.

REFERENCES

1. El Lakis M, Wiseman D, and Kebebew E. Management of Thyroiditis in Endocrine Glands. Elsevier. 764-66
2. Hennessey JV. Clinical review: Riedel's thyroiditis: a clinical review. J Clin Endocrinol Metab. 2011;96(10):3031-41.
3. Shafi AA, Saad NB, AlHarthi B. Riedel's thyroiditis as a diagnostic dilemma – A case report and review of the literature. Ann Med Surg (Lond). 2020;52:5-9.
4. Zala A, Berhane T, Juhlin CC, Calissendorff J, Falhammar H. Riedel Thyroiditis. J Clin Endocrinol Metab. 2022;105(9):dgaa468.
5. Blanco VM, Páez CA, Victoria AM, Arango LG, Arrunategui AM, Escobar J, Martínez V, Guzmán GE. Riedel's Thyroiditis: Report of Two Cases and Literature Review. Case Rep Endocrinol. 2019;2019:5130106.
6. Guimaraes VC. 2010 Subacute and Riedel's thyroiditis. In: Jameson JL, De Groot LJ eds. Endocrinol: adult and pediat. 6th ed. Philadelphia: Elsevier; 1600-1603
7. Kumar N, Gupta R, Sayed S, Moloo Z, Vinayak S, Ahmed M. Difficulties in diagnosis of Riedel's thyroiditis on aspiration cytology: A case report and brief review of the literature. Diagn Cytopathol. 2019;47(5):512-516.
8. Gosi SKY, Nguyen M, Garla V V. Riedel Thyroiditis. StatPearls. Fatourehchi MM, Hay ID, McIver B, Sebo TJ, Fatourehchi V. Invasive fibrous thyroiditis (Riedel thyroiditis): the Mayo Clinic experience, 1976-2008. Thyroid. 2011;21(7):765-72. 2021(7):765-72.
9. Falhammar H, Juhlin CC, Barner C, Catrina SB, Karefylakis C, Calissendorff J. Riedel's thyroiditis: clinical presentation, treatment and outcomes. Endocrine. 2018;60(1):185-192.
10. Dahlgren M, Khosroshahi A, Nielsen GP, Deshpande V, Stone JH. Riedel's thyroiditis and multifocal fibrosclerosis are part of the IgG4-related systemic disease spectrum. Arthritis Care Res (Hoboken). 2010;62(9):1312-8.



InaJEMD
Indonesian Journal of Endocrinology
Metabolism and Diabetes