

Turner Syndrome Mosaicism 46,Xx/45,X with Graves' Disease: A Case Report

Faisal Rozi Sembiring¹, Santi Syafril^{2*}

¹Departement of Internal Medicine, Faculty of Medicine, Universitas Sumatera Utara/Adam Malik Hospital, Medan, Indonesia

²Departement of Internal Medicine, Division of Endocrinology Metabolic and Diabetes, Faculty of Medicine, Universitas Sumatera Utara/Adam Malik Hospital, Medan, Indonesia

***Corresponding Author:**

Santi Syafril, Department of Internal Medicine, Division of Endocrinology Metabolic and Diabetic, Faculty of Medicine, Universitas Sumatera Utara/Adam Malik Hospital, Medan, Indonesia. E-mail: syafril.santi@yahoo.com

ABSTRACT

Turner syndrome (TS) is a condition in females missing the second sex chromosome (45,X) or parts thereof. It is a rare genetic condition with a wide range of clinical stigmata, such as short stature, delayed puberty and infertility, congenital malformations, and endocrine disorders. TS with chromosomal mosaicism (TSM) is a less severe and less frequent form of TS, who has less pronounced signs and symptoms than the classic TS. A 21-year-old woman with TSM and Graves' disease (GD) is reported. She presented with fatigue, sweating, palpitation, tremor, and the absence of menstruation or breast development. Further investigation reveals diffuse enlargement of thyroid gland and hyperthyroidism symptoms. Laboratory testing shows elevated fT4, low TSH, and elevated TSH receptor antibody levels. Previous chromosomal analysis showed a mosaicism: 46,XX,dup(X) (q28q21.2)[36]/45,X[4]. She is then treated with thiamazole and oral beta-blocker. Thyroid abnormalities is common in TS, especially in adult females. This including Hashimoto's thyroiditis and GD. But TS presenting with hyperthyroidism is rare, with most of the cases were reported happens in adult females. Mosaicism in TS resulted in less severe signs and symptoms than the classic TS. Therefore, based on the variabilities, it is often undetected. We reported a rare case of TSM with GD. We observed that mosaicism in this TS patient resulted in less severe GD symptoms, and the response to conventional treatment with thiamazole and oral beta-blocker was satisfactory.

Keywords: Turner's syndrome, mosaicism, graves' disease, hyperthyroidism

BACKGROUND

Turner syndrome (TS) is a condition among phenotypic females with a karyotype containing one X chromosome and complete or partial absence of the second sex chromosome,

associated with one or more typical clinical manifestations of TS, such as evidence of growth failure, short stature or has a strong likelihood of short stature (e.g., short parents and short predicted adult height or already pubertal at

the time of diagnosis), hypergonadotropic hypogonadism, congenital malformations, infertility, and a constellation of other disorders that are common in TS.¹ It was described by many scientists but it now carries the name of Henry H. Turner, who in his report in 1938, described the syndrome with the triad of infantilism, webbing of the skin and neck, and deformity of the elbow (*cubitus valgus*).² Later in 1959, it was found that the disease was caused by sex chromosomal abnormality.³

TS affects 25-50 per 100.000 females and can involve multiple organs through all stages of life, necessitating a multidisciplinary approach to care. It is the only viable monosomy syndrome caused by partial or complete loss of one of the two sex chromosomes.^{1,4} It is generally accepted that 45% of TS cases are classic TS that is associated with non-mosaic monosomy (45,X), while the remainder is associated with mosaic aberrations of chromosome X in 20–35% of cases, and with X chromosome rearrangements in 10–35% of cases. The presence of mosaic in chromosomal karyotyping in TS is often called Turner syndrome with mosaicism (TSM).⁵ Monosomy or classic TS is diagnosed earlier than other sex chromosome aneuploidies, such as Klinefelter syndrome. Median age of TS diagnosis is at 15 years; on average it is 12 years earlier than others. This is probably due to a more severe phenotype that may already be present in the fetus.⁵

Autoimmune thyroid diseases (AITD) are the most prevalent organ-specific state, and the occurrence of thyroid peroxidase antibodies indicates the presence of autoimmune thyroid disease.⁶ Several mechanisms have been proposed to explain the increased susceptibility to autoimmune disease in TS, including haploinsufficiency of X chromosome-related genes. On the X chromosome, there are at least ten genes that are involved in immunoregulatory functions. Haploinsufficiency of the *FOXP3* gene,

located in the Xp11.23 region, may contribute to increasing the susceptibility of TS women to AITDs.⁷ Additionally, alterations of both humoral and cellular immunity profiles have been suggested as possible mechanism leading to autoimmunity in TS.⁹

AITDs had been reported to be more frequent in women with TS than in the general population. They include Hashimoto's thyroiditis (HT) - which is considered the most common AITD in TS, and Graves' disease (GD) - which causes hyperthyroidism.⁹ A recent meta-analysis revealed that the prevalence of AITDs among TS population was 38.6%,¹⁰ higher than previous reviews done by Gravholt that reporting 15% as the prevalence.¹¹ Although a higher incidence of GD might also be expected in TS patients, based on the perspectives of pathogenic mechanism in AITD, this syndrome is significantly more infrequent than expected. The aim of this case report is to report a rare case of GD in a woman with TSM.

CASE ILLUSTRATION

A 21-year-old woman came to our hospital and complained of fatigue, sweating, palpitations, and tremors lasting for more than 2 months. Previous medical history was Turner syndrome, diagnosed based on chromosomal karyotyping in 2019. The sampling from 40 cells revealed mosaic 46,XX,dup(X)(q28q21.2)[36]/45,X[4]. During the initial physical examination, the patient's heart rate was 124 beats/minute, the blood pressure and body temperature were of normal value. Family history showed nothing that was relevant. We also found diffuse thyroid gland enlargement and fine finger tremor, but exophthalmos was not present. Her height was 142 cm, weight was 41.9 kg, and body mass index was 20.77 kg/m² (normal). Further examination revealed amastia (Tanner stage 1) and insubstantial pubic and axillary hair (Tanner stage 2). Oral estradiol has been prescribed in

the past due to primary amenorrhea, but with unsatisfactory results.

Hormonal tests, pelvic and thyroid ultrasound, and chest x-ray were performed. Thyroid function analysis presented that the sensitive thyroid stimulating hormone (TSH) level was <0.005 mIU/mL (normal range 0.350-4.940 mIU/mL), the free T4 (fT4) level was 6.48 ng/dL (normal range 0.93-1.70 ng/dL), and TSH receptor antibody (TRAb) level was 10.1 IU/L (normal range ≤ 1.75 IU/L). Other hormonal tests were also performed, with prolactin level was 5.04 ng/mL (normal range 5.18-26.53 ng/mL), luteinizing hormone (LH) level was 37.01 mIU/mL (normal range ≤ 15.97 mIU/mL), follicle stimulating hormone (FSH) level was 118.37 mIU/mL (normal range 0.57-8.77 mIU/mL), and estradiol level was <20 pg/mL (normal range <62 pg/mL for Tanner stage 2). Thyroid ultrasound revealed enlargement of the thyroid gland with hyper vascular activity. Pelvic ultrasound by a gynecologist presented that the uterus and both ovaries were relatively small. Chest x-ray was in a normal state.

Based on the result, we diagnosed the patient with Graves' disease, Turner syndrome mosaicism, and hypergonadotropic hypogonadism. Thiamazole treatment was soon started, and the dose was adjusted accordingly based on the thyroid hormone level that was regularly monitored. An oral beta-blocker was given based on the clinical presentation. Nine months after initial therapy, hyperthyroid symptoms were absent and the thyroid function analysis was of normal value. Her body weight has increased to 54 kg, but the height remains the same as before. We planned long-term follow-up on this patient since the patient, and her parents refused definitive treatment option. As of the latest follow-up, the euthyroid state is maintained with a low dose thiamazole.

DISCUSSION

This report describes a young woman with clinical signs and symptoms of classical GD and TSM. The karyotype was 46,XX,dup(X)(q28q21.2)[36]/45,X[4] with evidence of mosaicism (Fig.1). Mosaicism in TS resulted in a less severe phenotype than monosomy TS, because in mosaic individuals only some cells express the mutant allele while others express only normal alleles.¹ Most women with 46,XX/45,X mosaicism were detected incidentally and usually would not require a follow-up. The phenotype in these women was often unremarkable. While they were slightly shorter on average, this group of women went through menarche and menopause at an average age, had an average number of children, and were not at increased risk of pregnancy loss.¹³ TSM cases, on average, were diagnosed 8 years later than the monosomy cases. This was due to a less severe clinical signs and symptoms.¹⁴ Our patient was diagnosed with TSM during adolescence, with a lack of secondary sex characteristics becoming the primary concern at the time. No cardiovascular anomaly or kidney abnormalities were present, as many classic TS patients would have. Additionally, hyperthyroidism symptoms were only noted more than 4 years after TS diagnosis was established.

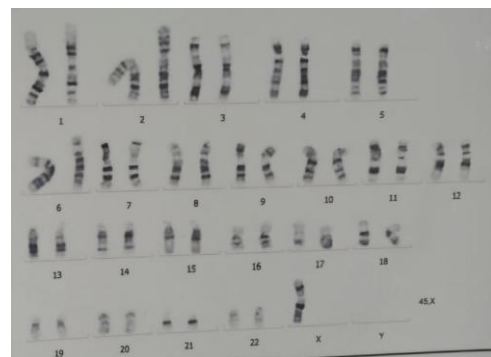


Figure 1. Cytogenetic analysis

The association of thyroid dysfunction and TS was well established, with the first report dated back to 1961.¹⁵ Since then, there were many reports of AITDs on patients with TS, although most of them were the case of hypothyroidism. A long-term follow-up study of 30 years found that hypothyroidism was present in 24% case of TS, but hyperthyroidism only present in 2.4% of the TS patients.¹⁶ Other report showed lower percentage, where there was only 2 out of 119 TS patients (1.7%) was confirmed hyperthyroidism due to GD.¹⁷

Currently, it is generally agreed that GD, especially during childhood and adolescence, is relatively rare. It is occurring mostly in patients with a family history of AITDs or other associated autoimmune disorders. It has been hypothesized that the incidence and frequency of chromosomal abnormalities are higher in patients with HT than in those with GD, however this is still poorly understood.¹⁸ In this case, we found no evidence of AITDs or other autoimmune disorders in family history.

It is also worth noting that some of GD cases in TS had been preceded earlier by HT, just like in general population, where there exists a continuum between HT and GD. A mechanism that has been hypothesized to account of these changes is the alteration in the biological activity of TRABs, from predominantly thyroid-blocking antibodies during the HT phase to thyroid-stimulating antibodies when GD manifests itself.¹⁹ This hypothesis, however, did not explain why the conversion from HT to GD was observed more frequently in chromosomopathies condition. The possible explanation could be that the switch was detected more frequently in the selected population with these chromosomopathies because these patients were already being monitored for thyroid disorders before GD presentation.²⁰ In this case, the patient had no record of prior hormonal tests, hence the preceding HT could not be concluded.

Biochemical picture at diagnosis and the clinical course of GD in TS patients were not different from general population. Valenzise et al. showed that the methimazole dose required to maintain euthyroidism during the therapy, and remission and relapse rates did not significantly differ from those observed in non-TS patients.²¹ All of the case reports on GD in TS patients used methimazole as a first line treatment, with satisfactory result. But in some cases, this treatment resulted in toxic hepatitis or other intolerances. Radioactive iodine therapy (RAIT) is thus indicated in these cases. However, there were only very few reports that have been published on RAIT in TS patients, so this option should be considered individually with taking into account of potential RAIT complications.²² Our patient showed significant improvement after 3 months of thiamazole treatment. The symptoms were absent after 6 months and her body weight was increased 12 kgs after 9 months. And since the patient and her parents refused definitive treatment, we planned for long-term follow-up focusing in clinical and biochemical profiles. Currently the euthyroid state is maintained with a low dose thiamazole.

CONCLUSION

We report a rare coexistence of TS mosaicism (46,XX/45,X) and Graves' disease in a young woman. AITDs in TS patients are higher than in the general population, but the presence of GD is relatively rare. In our case, thiamazole treatment showed significant improvements, and currently the patient is in euthyroid state with a low-dose thiamazole. However, the underlying mechanism of higher frequency of AITDs, especially GD, in TS patients is still poorly understood. The prognosis is relatively good, although comorbidities such as cardiovascular complications remain a problem. We recommend close follow-up on TSM patients with GD for a better quality of life.

REFERENCES

1. Gravholt CH, Andersen NH, Conway GS, Dekkers OM, Geffner ME, Klein KO, et al. Clinical practice guidelines for the care of girls and women with Turner syndrome: proceedings from the 2016 Cincinnati International Turner Syndrome Meeting. *Eur J Endocrinol* 2017;177(3):G1-G70.
2. Turner HH. A syndrome of infantilism, congenital webbed neck, and cubitus valgus. *Endocrinology* 1938;23(5):566-74.
3. Ford CE, Jones KW, Polani PE, De Almeida JC, Briggs JH. A sex-chromosome anomaly in a case of gonadal dysgenesis (Turner's syndrome). *Lancet* 1959;1:711-3.
4. Gravholt CH, Viuff M, Just J, Sandahl K, Brun S, van der Velden J, et al. The changing face of Turner syndrome. *Endocr Rev* 2023;44(1):33-69.
5. Iourov IY, Vorsanova SG, Yurov YB, Kutsev SI. Ontogenetic and pathogenetic views on somatic chromosomal mosaicism. *Genes (Basel)* 2019;10(5):379.
6. Naessen S, Eliasson M, Berntrop K, Kitlinski M, Trimpou P, et al. Autoimmune disease in Turner syndrome in Sweden: an up to 25 years' controlled follow-up study. *J Clin Endocrinol Metab* 2024;109(2):e602-12.
7. Zinn AR, Tonk VS, Chen Z, Flejter WL, Gardner HA, Guerra R, et al. Evidence for a Turner syndrome locus or loci at Xp11.2-p22.1. *Am J Hum Genet* 1998;63:1757-66.
8. Gawlik AM, Berdej-Szczot E, Blat D, Klekotka R, Gawlik T, Blaszczyk E, et al. Immunological profile and predisposition to autoimmunity in girls with Turner syndrome. *Front Endocrinol* 2018;9:307.
9. Bondi CA. Turner Syndrome Study Group. Care of girls and women with Turner syndrome: a guideline of the Turner Syndrome Study Group. *J Clin Endocrinol Metab* 2007;92:10-25.
10. Mohamed SOO, Elkhidir IHE, Abuzied AIH, Nouredin AAMH, Ibrahim GAA, Mahmoud AAA. Prevalence of autoimmune thyroid disease among the Turner syndrome patients: meta-analysis of cross sectional studies. *BMC Res Notes* 2018;11:842.
11. Gravholt CH. Aspects of the treatment of Turner syndrome. *Expert Opin Pharmacother* 2001;2(10):1633-47.
12. Wallis GA, Starman BJ, Zinn AB, Byers PH. Variable expression of osteogenesis imperfecta in a nuclear family is explained by somatic mosaicism for a lethal point mutation in the alpha 1(I) gene (COL1A1) of type I collagen in a parent. *Am J Hum Genet* 1990;46(6):1034-40.
13. Tuke MA, Ruth KS, Wood AR, Beaumont RN, Tyrrell J, Jones SE, et al. Mosaic Turner syndrome shows reduced penetrance in adult population study. *Genet Med* 2019;21(4):877-86.
14. El-Mansoury M, Barrenas M-L, Bryman I, Hanson C, Larsson C, Wilhelmsen L, et al. Chromosomal mosaicism mitigates stigmata and cardiovascular risk factors in Turner syndrome. *Clin Endocrinol (Oxf)* 2007;66(5):744-51.
15. Williams ED, Engel E, Forbes AP. Thyroiditis and gonadal dysgenesis. *N Eng J Med* 1964;270:805-10.
16. Livadas S, Xekouki P, Fouka F, Kanaka-Gantenbein C, Kaloumenou I, Mavrou A, et al. Prevalence of thyroid dysfunction in Turner's syndrome: a long-term follow-up study and brief literature review. *Thyroid* 2005;15(9):1061-6.
17. Wasniewska M, Corrias A, Messina MF, Crisafulli G, Salzano G, Valenzise M, et al. Graves' disease prevalence in a young population with Turner syndrome. *J Endocrinol Invest* 2010;33:69-70.
18. Casto C, Pepe G, Li Pomi A, Corica D, Aversa T, Wasniewska M. Hashimoto's thyroiditis and Graves' disease in genetic syndromes in pediatric age. *Genes* 2021;12:222.
19. Ludgate M, Emerson CH. Metamorphic thyroid autoimmunity. *Thyroid* 2008;10:1035-7.
20. Aversa T, Lombardo F, Corrias A, Salerno M, De Luca F, Wasniewska M. In young patients with Turner or Down syndrome, Graves' disease presentation is often preceded by Hashimoto's thyroiditis. *Thyroid* 2014;24(4):744-7.
21. Valenzise M, Aversa T, Corrias A, Mazzanti L, Cappa M, Ubertini G, et al. Epidemiology presentation and long-term evaluation of Graves' disease in children, adolescents and young adults with Turner syndrome. *Horm Res Pediatr* 2014;81:245-50.
22. Guseinova RM, Prosvirina AA, Korchagina MO, Trukhin AA, Sheremeta MS. Thyrotoxicosis in a patient with Turner syndrome: radioactive iodine therapy. *Probl Endocrinol* 2022;68(6):49-58.