

# Clinically Non-Functioning Pituitary Incidentaloma Presenting as Recurrent Episodes of Hypoglycemia

Nobian Andre<sup>1\*</sup>, Marco Vidor<sup>1</sup>, James Marcus<sup>1</sup>, Teddy Ervano<sup>2</sup>

<sup>1</sup>Department of Internal Medicine, Faculty of Medicine, Universitas Indonesia, Jakarta Indonesia

<sup>2</sup>Division of Endocrinology, Metabolism, and Diabetes, Department of Internal Medicine, Pasar Rebo General Hospital, Jakarta, Indonesia

**\*Corresponding author:**

Nobian Andre. Department of Internal Medicine, Faculty of Medicine, Universitas Indonesia, Jakarta Indonesia  
Email: nobian-andre@hotmail.com

## ABSTRACT

A pituitary adenoma is a tumor originating from the adenohypophysis. Pituitary adenomas are mostly discovered incidentally during radiological examinations performed for other purposes. Not all pituitary adenomas are functional. Non-functioning adenomas often present with symptoms due to mass effect and pituitary hormone deficiency. This case report presents a case of a 56-year-old man with type 2 diabetes mellitus who had an accidental finding of pituitary macroadenoma without overt hormone hypersecretion symptoms, but experienced recurrent hypoglycemia. Further investigation revealed low cortisol and insulin like growth hormone-1 levels, suggesting a Houssay phenomenon that leads to 'resolution' of diabetes due to hypopituitarism. Even in patients without overt symptoms of hormone hypersecretion, the possibility of subtle hypopituitarism due to tumor-induced pituitary dysfunction should not be overlooked. Patients with pituitary adenomas require evaluation by a multidisciplinary team involving endocrinology, neurosurgery, and ophthalmology.

**Keywords:** Hypopituitarism, non-functioning pituitary adenoma, pituitary incidentaloma, recurrent hypoglycemia

## INTRODUCTION

A pituitary adenoma is a tumor originating from the anterior pituitary (adenohypophysis). This tumor is the most common type of pituitary disorder, accounting for approximately 10–15% of all intracranial tumors.<sup>1,2</sup> Most pituitary tumors are benign and slow-growing. The pathogenesis of pituitary adenomas remains unclear. The majority of cases are sporadic, with genetic mutations being rarely characteristic of pituitary adenomas. Familial pituitary adenoma cases account for only about 5% of all pituitary tumors.<sup>1</sup>

Most pituitary adenomas are discovered incidentally on imaging performed for other reasons.<sup>1-3</sup> As a result, it is difficult to accurately estimate the prevalence of pituitary adenomas in the general population. Prevalence estimates extrapolated from autopsy and radiological data suggest an average of 16.7%, with autopsy findings at 14.4% and radiological imaging at 22.5%.<sup>1</sup> The detection rate of pituitary incidentalomas varies between 4–20% on CT scans and 10–38% on MRI.<sup>3</sup> A study from the UK reported a prevalence of pituitary adenomas

of 77.6 per 100,000 people<sup>2</sup>, while another study from Iceland found an incidence of 115 cases per 100,000 population.<sup>1</sup> Of all pituitary adenomas, approximately 43% are non-functioning, 40% are prolactinomas, 11% secrete growth hormone, and 6% secrete adrenocorticotropic hormone (ACTH).<sup>1</sup> Adenomas that secrete follicle-stimulating hormone (FSH), luteinizing hormone (LH), or thyroid-stimulating hormone (TSH) are rare.<sup>2</sup> The constellation of endocrine symptoms seen in patients with pituitary adenomas includes hormone hypersecretion or, conversely, pituitary hormone deficiency.<sup>2</sup> Functional adenomas can cause clinical syndromes such as acromegaly and Cushing's disease. In contrast, non-functioning adenomas often present symptoms due to mass effect and pituitary hormone deficiency. Hypopituitarism resulting from the tumor mass that compresses normal anterior pituitary tissue, and the pituitary stalk can lead to deficiencies in other pituitary hormones.<sup>4</sup> This case report presents a pituitary incidentaloma in a 56-year-old man who initially underwent a CT scan for nasopharyngeal cancer evaluation. Although he did not exhibit overt symptoms of hormone hypersecretion, it is possible that he experienced subtle hypopituitarism, particularly given his history of recurrent treatment for hypoglycemia in the context of hyperglycemic type 2 diabetes mellitus.

## CASE ILLUSTRATION

A 56-year-old male presented to the emergency department with complaints of decreased consciousness and seizures. There was no facial drop or unilateral weakness. Upon arrival at the emergency department, he was found to have low blood glucose. There was no nausea, vomiting, nor anorexia. During hospitalization, an electroencephalogram (EEG) was performed which yielded normal results. The patient also reported that he frequently

experienced fatigue, dizziness, and intermittent episodes of blurred vision. These events were accompanied by low blood glucose levels noted over the past several months. Over the past six months, he has already had two episodes of hypoglycemia requiring hospitalization.

Previously, the patient was diagnosed with diabetes mellitus for three years prior to admission. He initially presented with dizziness and a blood glucose level of 400 mg/dL at a primary care clinic. He denied previous symptoms of polyphagia, polydipsia, polyuria, nor significant weight loss. He had received regular treatment at Pasar Rebo General Hospital over the past year, with reportedly controlled but generally low blood glucose levels. He occasionally monitors his blood glucose levels at home, typically when experiencing symptoms such as palpitations, fatigue, or cold sweats, with readings ranging from 70–100 mg/dL and a most recent HbA1c of 5.3%. His last prescribed medications were metformin 500 mg once daily and glimepiride 4 mg once daily. His appetite was reported as good, eating three meals daily with no nausea or vomiting. According to his wife, at the time of his hypoglycemic episode, he had not yet taken his diabetes medication prior to being found unconscious.

Seven months prior to admission, the patient sought consultation with an otolaryngologist (ENT) specialist due to frequent epistaxis. There was no history of head or facial trauma. He reported a decline in hearing that had been present for about ten years, previously assessed and attributed to a neural hearing disorder. He denied visual disturbances, a sensation of fullness in the ears, or any neck masses. Nasal endoscopy was performed, but due to difficulty evaluating the retropharyngeal area, a head computed tomography (CT) scan was performed. The CT scan revealed brain mass, suspected to be a pituitary macroadenoma, and he was then referred to neurosurgery

department in Fatmawati Central General Hospital. However, due to the absence of any symptoms attributable to the tumor, the patient never visited the neurosurgery clinic. He denied symptoms such as widening of the jaw or face, prominent cheekbones, thickening of the lips or tongue, or enlargement of hands and feet. There was no history of nipple discharge or breast enlargement. He also denied palpitations, hand tremors, insomnia, heat intolerance, exophthalmos, irritability, abdominal or thigh striae, bluish skin rashes, double vision, visual field narrowing, or headache.

On arrival, the patient's vital signs were within normal limits. His body mass index was 30.83 kg/m<sup>2</sup> (obesity grade II). A thorough physical examination revealed no mandibular enlargement, no increased prominence of the frontal or zygomatic bones, no thickening of the lips or macroglossia, and no moon face. There was no exophthalmos. The thyroid was not palpable, and there was no buffalo hump. Chest examination found no signs of gynecomastia, while abdomen examination found to be distended, with no livid striae discovered. Extremities were within normal limits

with no tremors.

A blood sample was then drawn, and the complete blood count, kidney function tests and liver enzymes were within normal limits (urea/creatinine/eGFR: 43/1.24/68, AST/ALT: 73/32 U/L). There was slight hyponatremia of 133 mEq/L. Blood sugar at presentation was low at 35 mg/dL. He received 40% dextrose, which corrected his glucose level temporarily, but he subsequently experienced another episode of hypoglycemia. The following is the trend of his glucose levels.

His HbA1c was 5.3%. This patient had also previously undergone a brain CT scan at five months prior to current admission. The CT scan was initially performed to evaluate nasopharyngeal carcinoma. However, it revealed a round mass in the sella turcica, measuring 1.4 x 1.7 x 1.4 cm, which showed strong post-contrast enhancement, with a differential diagnosis of pituitary macroadenoma.

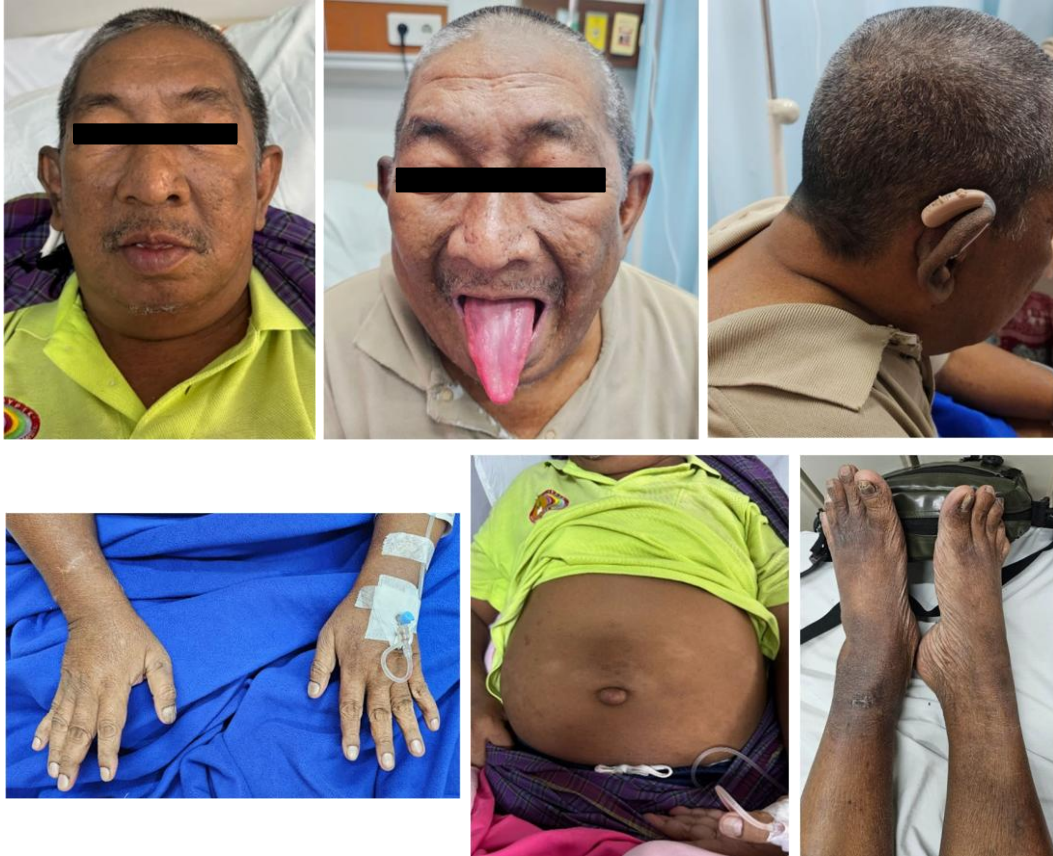The patient was diagnosed with recurrent hypoglycemia in the context of obese type 2 diabetes mellitus, along with a concurrent non-functioning pituitary macroadenoma and suspected hypopituitarism. Further investigation

**Table 1.** Blood glucose levels

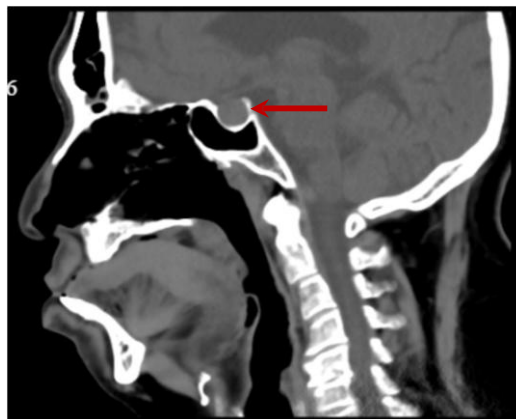Time	Blood Glucose (mg/dL)	Intervention
01:00	Capillary: Low, Venous: 35	Dextrose 40%, 3 flacons
03:50	63	Dextrose 40%, 2 flacons; Dextrose 10% 500 cc/12 hours
05:05	103	Dextrose 10% 500 cc/12 hours
06:05	27	Dextrose 40%, 2 flacons; meal; Dextrose 10% 500 cc/12 hours
07:20	112	Dextrose 10% 500 cc/12 hours
11:00	110	Dextrose 10% 500 cc/12 hours
13:25	79	Dextrose 10% 500 cc/12 hours
15:52	44	Dextrose 40%, 3 flacons; Dextrose 10% 500 cc/12 hours
17:16	79	Dextrose 40%, 2 flacons; Dextrose 10% 500 cc/12 hours
19:32	96	Dextrose 10% 500 cc/12 hours
22:05	40	Dextrose 40%, 2 flacons; Dextrose 10% 500 cc/12 hours
23:05	50	Dextrose 40%, 2 flacons; Dextrose 10% 500 cc/12 hours
23:59	175	Dextrose 10% 500 cc/12 hours
01:30	50	Dextrose 40%, 3 flacons; Dextrose 10% 500 cc/12 hours
03:10	77	Dextrose 40%, 3 flacons; Dextrose 10% 500 cc/12 hours
04:50	75	Dextrose 40%, 3 flacons; Dextrose 10% 500 cc/12 hours
06:24	82	Dextrose 40%, 4 flacons; Dextrose 10% 500 cc/12 hours
07:45	152	Dextrose 10% 500 cc/12 hours

revealed low cortisol and IGF-1 levels (0.9 mcg/dL and 35 ng/mL, respectively). His prolactin level was 104.7 ng/mL, with a normal TSH (0.69 mIU/L) and normal free thyroxine (1.19 ng/dL). Therefore, we consider that this patient was

experiencing subtle symptoms of hypopituitarism due to the compression of normal pituitary tissue by a non-functioning macroadenoma mass, resulting in pituitary hormone deficiency manifested as recurrent hypoglycemia.



**Figure 1.** Clinical photograph of the patient. The patient showed no signs of prognathism, macroglossia, acral enlargement, buffalo hump, or striae livide.



**Figure 2.** CT scan shows a pituitary adenoma (red arrow).

## DISCUSSION

The pituitary gland is located inferior to the hypothalamus, surrounded by the sphenoid bone in a basket-like structure called the sella turcica. It is situated below the optic chiasm.<sup>2</sup> The pituitary gland consists of two lobes: the anterior lobe (also called the adenohypophysis) and the posterior lobe (also called the neurohypophysis). The anterior pituitary produces six hormones: prolactin (PRL), growth hormone (GH), ACTH, LH, FSH, TSH. Pituitary adenoma is a tumor originating from the anterior pituitary (adenohypophysis). These tumors can be classified based on its size, function, and cell of origin:<sup>1,2</sup>

1. According to size: microadenoma: diameter <10 mm (<1 cm), macroadenoma: diameter ≥10 mm (≥1 cm), giant adenoma: diameter ≥40 mm (≥4 cm).
2. According to functional status: functional: tumor cells cause increased secretion of one or more anterior pituitary hormones, non-functional: tumor cells do not secrete excess hormones, but may compress normal anterior pituitary tissue and the pituitary stalk, resulting in deficiencies of other pituitary hormones (hypopituitarism).
3. According to cell origin: pituitary adenomas are neoplasms arising from monoclonal cells, and rarely from a combination of the following cell types; somatotroph: secretes GH, lactotroph: secretes prolactin, corticotroph: secretes ACTH, gonadotroph: secretes LH/FSH, thyrotroph: secretes TSH

The presentation of pituitary adenomas depends on the size of the tumor (mass effect symptoms) and its functional status (hormonal symptoms). Patients may be asymptomatic if the tumor is small and

not hormonally active, as frequently seen in pituitary incidentalomas. Patients with pituitary macroadenomas typically present with symptoms related to mass effect and hormonal disturbances.<sup>1</sup>

- A. Symptoms of mass effect: visual disturbances: suprasellar extension of a pituitary adenoma can compress the superior aspect of the optic chiasm, resulting in visual field defects. Bitemporal hemianopsia is the most common pattern. Involvement of the oculomotor nerves can cause diplopia.<sup>1, 2</sup> Direct invasion of the optic nerve (cranial nerve II) may lead to decreased visual acuity.<sup>2</sup> Therefore, visual function should be clinically evaluated through tests of visual acuity and visual fields.<sup>3</sup> Headache: a nonspecific symptom and may indicate pressure on the dura mater or the sellar diaphragm exerted by the tumor mass. This symptom is more commonly seen in non-functioning adenomas, as these tumors do not secrete enough hormone to cause endocrine symptoms and instead present with mass effect<sup>2</sup>, cranial nerve palsies: if the adenoma extends laterally into the cavernous sinus, it can compress cranial nerves III (oculomotor), IV (trochlear), and VI (abducens), leading to ocular motor disturbances such as double vision<sup>2</sup>, hormone deficiency (hypopituitarism): deficiency of one or more anterior pituitary hormones can occur due to compression of the pituitary stalk or destruction of normal pituitary tissue by the tumor mass. Gonadotropin deficiency causes amenorrhea in women and erectile dysfunction in men. GH deficiency leads to fatigue and weight gain. TSH deficiency results in fatigue, weight gain, cold intolerance, and constipation. ACTH deficiency causes fatigue, weight loss, hypotension, dizziness, nausea, vomiting, abdominal pain, and arthralgia.<sup>1</sup> Symptoms of hypopituitarism are present in about 30% of pituitary adenomas.<sup>2</sup>
- B. Symptoms of hormone hypersecretion: prolactin hypersecretion: in women, this causes oligomenorrhea or amenorrhea and galactorrhea. In men, it leads to erectile dysfunction and gynecomastia. Elevated prolactin also suppresses gonadotropin levels, resulting in infertility, decreased libido, and osteoporosis in both sexes<sup>1</sup>, GH hypersecretion (acromegaly): symptoms include an increase in ring or shoe size, course

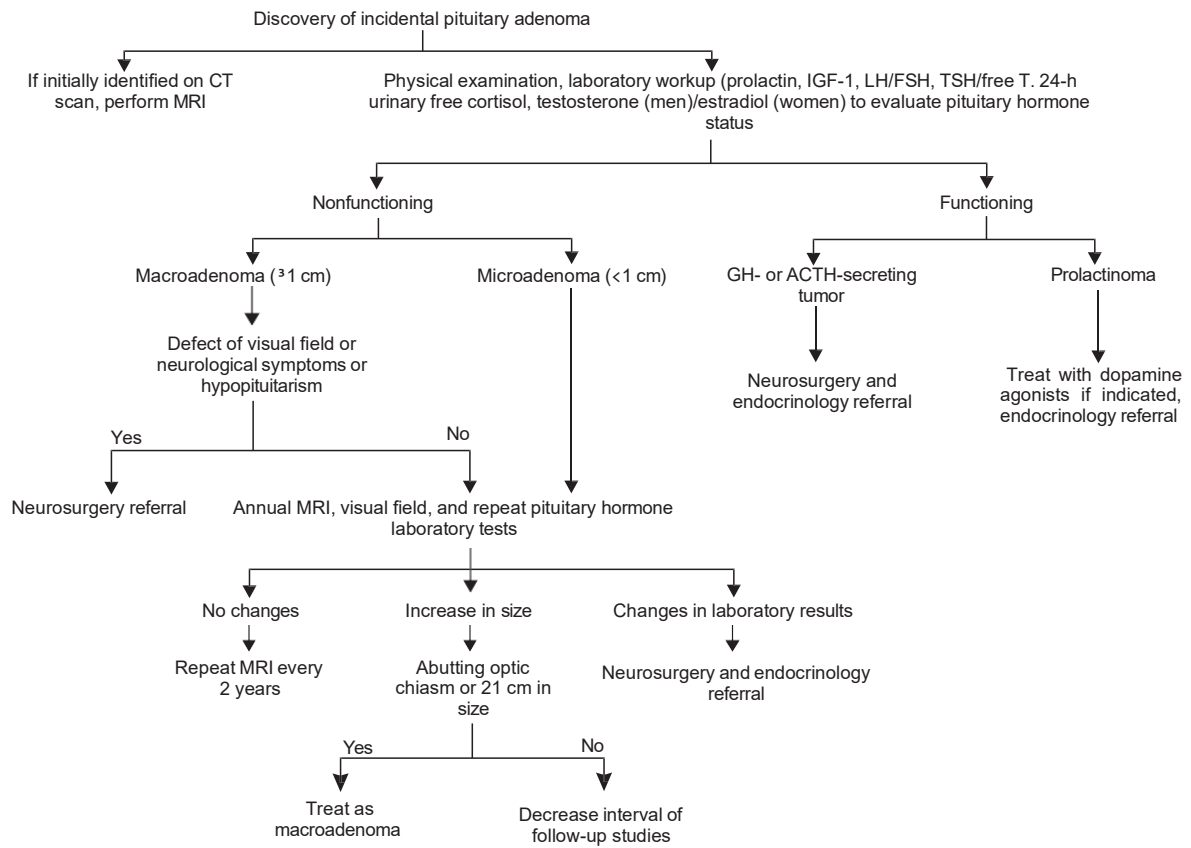
facial features, prominent frontal bone, enlarged nose, prognathism (enlarged mandible), and macroglossia (enlarged tongue). Patients may also present with hypertension and obstructive sleep apnea at diagnosis.<sup>1</sup>, ACTH hypersecretion (Cushing's disease): manifestations include weight gain, rounded face (moon face), supraclavicular fat pads, purple (livide) striae on the abdomen, proximal muscle weakness, easy bruising (ecchymosis), bone fractures, and mood disturbances.<sup>1</sup>, TSH hypersecretion (central hyper-thyroidism): symptoms include palpitations, weight loss, tremor, diarrhea, heat intolerance, and insomnia.<sup>1</sup>, Gonadotropin hypersecretion: excess secretion can cause ovarian overstimulation, increased testosterone levels, and testicular enlargement. However, many gonadotropin-secreting adenomas do not produce clinically significant hormone excess and are thus considered non-functioning tumors. These may still cause pituitary insufficiency due to compression of the pituitary stalk or destruction of normal pituitary tissue by the tumor mass.<sup>4</sup>

The detection of pituitary adenomas requires radiographic imaging. Most pituitary adenomas are incidentally detected on CT scans performed for other reasons. However, magnetic resonance imaging (MRI) is the imaging modality of choice for diagnosing pituitary disorders due to its superior sensitivity and specificity for soft tissue evaluation (sensitivity 61–72%, specificity 88–90% for sellar masses).<sup>2,4</sup> Contrast-enhanced MRI is necessary to differentiate pituitary tumors from aneurysms and assess for intrasellar hemorrhage.<sup>1</sup>

When a pituitary mass is found incidentally, diagnostic workup should determine whether it is functional or non-functional.<sup>2</sup> The 2011 Endocrine Society guidelines for pituitary incidentalomas recommend

comprehensive pituitary function assessment, even in asymptomatic patients.<sup>5</sup> Biochemical evaluation includes<sup>1</sup> prolactin: serum levels generally correlate with tumor size. Prolactin <200 ng/mL suggests microadenoma, while levels >200–250 ng/mL indicate prolactin-secreting macroadenoma.<sup>1,2</sup>, IGF-1/GH: serum IGF-1 screens for acromegaly. In clinically suspected cases with normal IGF-1, GH levels are measured after 75 grams of oral glucose tolerance test. Failure to suppress GH below 1 ng/dL confirms acromegaly.<sup>1</sup>, morning serum cortisol: screening for Cushing's disease includes late-night salivary cortisol, 24-hour urinary free cortisol, or 1mg overnight dexamethasone suppression test (DST). A post-DST cortisol  $\geq 1.8$  mcg/dL indicates hypercortisolism. Biochemical confirmation requires ACTH measurement: elevated ACTH suggests corticotroph adenoma.<sup>1</sup>, LH, FSH, estradiol, testosterone: Low sex hormones with normal/low LH/FSH indicate hypogonadotropic hypogonadism. Interpretation is confounded by oral contraceptives in women, and FSH naturally rises post-menopause.<sup>1</sup>, TSH, free T4: TSH-secreting adenomas show elevated T4/T3 with normal/high TSH (central hyperthyroidism pattern).

The finding of a pituitary adenoma in this case report is classified as an incidentaloma because the pituitary mass was discovered during a head CT scan performed for another purpose, in this case, nasopharyngeal malignancy screening by the ENT specialist. With a diameter of  $\geq 1$  cm, the lesion in this patient is categorized as a macroadenoma. According to the 2011 Endocrine Society guidelines for pituitary incidentalomas, a comprehensive assessment of pituitary hormone function is necessary for such patients. The clinical approach for pituitary incidentaloma is shown in Figure 3. Clinically, this patient did not exhibit symptoms of anterior pituitary hormone hypersecretion (GH, prolactin, ACTH, TSH). Hormone laboratory tests in this patient also showed normal TSH and free thyroxine levels (0.69 mIU/L and 1.19 ng/dL respectively). Due to several limitations, we could not obtain the LH/FSH as well as testosterone levels in this patient. Although the prolactin level was elevated, it did not reach the 200 ng/mL cutoff required to categorize it as a



ACTH: adrenocorticotropic hormone; FSH: follicle-stimulating hormone; GH: growth hormone; IGF-1: insulin-like growth factor 1; LH: luteinizing hormone; T Thyroxine, TSH: thyroid-stimulating hormone

**Figure 3.** Flowchart for the evaluation and management of pituitary incidentaloma.<sup>2,5</sup>

Based on pituitary hormone evaluation, the patient falls into the category of non-functioning macroadenoma.

There are several causes of hypoglycemia in diabetic patients, such as reduced food intake, improper medication administration, decreased kidney function, and hepatic dysfunction. In this case, we attempted to rule out iatrogenic causes of hypoglycemia in a type 2 diabetes mellitus patient who was taking antidiabetic medications. It was noted that the patient was taking metformin, which has a low risk of causing hypoglycemia.<sup>6</sup> Although the patient was also receiving glimepiride, its risk of causing hypoglycemia is relatively lower compared to other sulfonylureas, which are known for their higher hypoglycemic risk. It is also important to note that the patient's hypoglycemic episodes occurred before he took his diabetes medications and there was no history of reduced food intake beforehand. Additionally, the patient's kidney and liver function were relatively preserved, which did not increase the risk of hypoglycemia.

Hormone laboratory tests in this patient showed low cortisol level (0.9 mcg/dL), suggesting an adrenal insufficiency that can lead to hypoglycemia in this patient. Given the presence of a pituitary macroadenoma, it is likely for the adrenal insufficiency to be secondary. However, due to several limitations, we could not obtain the ACTH level in this patient. Furthermore, the occurrence of hypoglycemia in this patient may still be linked to Houssay phenomenon, first described by Dr. Bernardo Houssay in 1931,<sup>7</sup> which involves the resolution of diabetes due to hypopituitarism.<sup>8</sup> This phenomenon explains recurrent hypoglycemia in diabetic patients with hypopituitarism. In this case, hypopituitarism likely involves deficiencies in ACTH, cortisol, and GH—several key counterregulatory hormones that oppose insulin during hypoglycemia. The absence of these hormones disrupts glucose regulation, leading to recurrent hypoglycemia.

Laboratory tests in this patient revealed low cortisol level (0.9 mcg/dL) and low IGF-1 level (35 ng/mL), consistent with hypopituitarism secondary to the macroadenoma. These findings align with the mechanism of Houssay phenomenon, where pituitary hormone deficiencies impair counterregulatory responses, resulting in hypoglycemia despite the patient's type 2 diabetes status. Therefore, we propose that the recurrent hypoglycemic episodes encountered in this patient were attributable to a non-functioning adenoma that compresses normal anterior pituitary tissue and the pituitary stalk, causing hypopituitarism.

The management of pituitary adenomas can be divided into functional and non-functional tumors (as shown in Figure 3). For non-functional adenomas, not all cases require surgery. Transsphenoidal resection is indicated in patients with visual field deficits due to tumor compression, other visual abnormalities (e.g., ophthalmoplegia), optic nerve or chiasmal compression on imaging, pituitary apoplexy, loss of endocrine function, and significant tumor growth progression. For non-functioning adenomas not requiring surgery, regular monitoring is essential to assess tumor growth and hypopituitarism development. Head MRI should be performed annually for the first three years, less frequently if stable thereafter.<sup>1</sup>

<sup>2</sup> Repeat biochemical testing via endocrine panels is not recommended unless tumor enlargement occurs or patients develop hormone hypersecretion symptoms.<sup>2</sup>

## CONCLUSION

Pituitary adenomas are mostly discovered incidentally during radiological examinations performed for other purposes. Tumor size, functional status (hyper- or hypopituitarism), and symptoms of mass effect guide subsequent management. Patients with pituitary adenomas require evaluation by a multidisciplinary team involving endocrinology, neurosurgery, and

ophthalmology. Even in patients without overt symptoms of hormone hypersecretion, the possibility of subtle hypopituitarism due to tumor-induced pituitary dysfunction should not be overlooked.

## REFERENCES

1. Russ S, Anastasopoulou C, Shafiq I. Pituitary Adenoma. In: StatPearls [Internet]. Treasure Island (FL): StatPearls Publishing; [updated 2023 Mar 27; cited 2025 19 February]. Available from: <https://www.ncbi.nlm.nih.gov/books/NBK554451/>.
2. Lake M, Krook L, Cruz S. Pituitary Adenomas: An Overview: Am Fam Physician; 2013 [updated Unknown; cited 19 February 2025]. Available from : <https://www.aafp.org/pubs/afp/issues/2013/0901/p319.html>.
3. Snyder P. Pituitary incidentalomas [Internet]. UpToDate; [updated 10 April 2023; cited 2025 19 February]. Available from: <https://www.uptodate.com/contents/pituitary-incidentalomas>.
4. PDQ® Adult Treatment Editorial Board. Pituitary Tumors Treatment (PDQ®)—Health Professional Version: National Cancer Institute; [updated 17 December 2024; cited 2025 19 February]. Available from: <https://www.cancer.gov/types/pituitary/hp/pituitary-treatment-pdq>.
5. Freda PU, Beckers AM, Katznelson L, Molitch ME, Montori VM, Post KD, et al. Pituitary incidentaloma: an endocrine society clinical practice guideline. *J Clin Endocrinol Metab*. 2011;96(4):894-904.
6. Luna E, Feinglo M. Oral Agents in the Management of Type 2 Diabetes Mellitus: Am Fam Physician; 2001 [updated unknown; cited 2025 19 February]. Available from: <https://www.aafp.org/pubs/afp/issues/2001/0501/p1747.html>.
7. Pramanik S, Bhattacharjee R, Mukhopadhyay P, Ghosh S. Lesson of the month 2: Houssay phenomenon - hypopituitarism leading to remission of diabetes. *Clin Med ( Lond)*. 2016;16(3):294-6.
8. Gaffar Mohammed M, Baloch J, Alsahhar AM, Alhabashi BM. Recurrent Hypoglycemia in Diabetic Patient With Hypopituitarism: The Houssay Phenomenon. *Cureus*. 2021;13(2):e13422.